

Secondary glaucoma associated with bilateral *Aspergillus niger* endophthalmitis in an HIV-positive patient: case report

Glaucoma secundário a endoftalmite bilateral por Aspergillus niger em paciente HIV-positivo: relato de caso

Jayter Silva Paula¹
Agostinho Bryk Junior²
Argemiro Lauretti Filho³
Erasmão Romão⁴

ABSTRACT

Aspergillus endophthalmitis is usually related to systemic or local dissemination in immunosuppressed subjects. The authors report a rare case of severe bilateral glaucoma secondary to an intraocular infection with *Aspergillus niger*, in the absence of any detectable focus of aspergillosis, in an HIV-infected patient. There were no confirming signs of injection drug use, and the agent was isolated after inoculation in experimental animals. This case shows that *Aspergillus* endophthalmitis should be considered in non-injecting drug users and HIV-infected patients even in the absence of systemic aspergillosis.

Keywords: *Aspergillus niger*/isolation & purification; Endophthalmitis/complications; Glaucoma/etiology; Eye infections, fungal; HIV; Immunocompromised host; Case reports [publication type]

Trabalho realizado no Departamento de Oftalmologia, Otorrinolaringologia e Cirurgia de Cabeça e Pescoço. Faculdade de Medicina de Ribeirão Preto, Universidade de São Paulo.

¹ Professor colaborador do Departamento de Oftalmologia, Otorrinolaringologia e Cirurgia de Cabeça e Pescoço. Faculdade de Medicina de Ribeirão Preto, Universidade de São Paulo - USP - Ribeirão Preto (SP) - Brasil.

² Médico residente do Departamento de Oftalmologia, Otorrinolaringologia e Cirurgia de Cabeça e Pescoço. Faculdade de Medicina de Ribeirão Preto - USP - Ribeirão Preto (SP) - Brasil.

³ Professor associado do Departamento de Oftalmologia, Otorrinolaringologia e Cirurgia de Cabeça e Pescoço. Faculdade de Medicina de Ribeirão Preto - USP - Ribeirão Preto (SP) - Brasil.

⁴ Professor associado do Departamento de Oftalmologia, Otorrinolaringologia e Cirurgia de Cabeça e Pescoço. Faculdade de Medicina de Ribeirão Preto - USP - Ribeirão Preto (SP) - Brasil.

Correspondence to: Jayter Silva de Paula. Departamento de Oftalmologia, Otorrinolaringologia e Cirurgia de Cabeça e Pescoço - Hospital das Clínicas de Ribeirão Preto - 12º andar - Campus USP. Av. Bandeirantes, 3900 - Ribeirão Preto (SP) CEP 14049-900
E-mail: jayterdepaula@yahoo.com.br

Recebido para publicação em 08.11.2005
Aprovação em 16.12.2005

Nota Editorial: Depois de concluída a análise do artigo sob sigilo editorial e com a anuência da Dra. Mariza Toledo de Abreu sobre a divulgação de seu nome como revisora, agradecemos sua participação neste processo.

INTRODUCTION

Aspergillus is a fungus with septate hyphae about 2 to 4 µm in diameter identified on the basis of its macroscopic and microscopic aspect in culture⁽¹⁾. Spore inhalation is common but the disease is rare. However, massive spore inhalation by a healthy person can cause diffuse acute pneumonia⁽¹⁾. Patients with aspergillosis usually present some type of immunodeficiency⁽¹⁾. Penetrating trauma to the eye, cataract surgery and hematogenic dissemination are conditions associated with *Aspergillus*-induced endophthalmitis⁽²⁻³⁾. We report here a case of severe bilateral glaucoma secondary to an intraocular infection with *Aspergillus niger*.

CASE REPORT

A 27-year-old white woman was referred to ophthalmological examination, with a progressive bilateral decrease of visual acuity that culminated in total loss of vision. The patient denied any previous ocular disease, traumatic injury or injection drug use. Her husband was sexually promiscuous.

Ophthalmologic examination revealed no light perception in the right eye (OD) and perception of hand movements in the left eye (OS). Biomicroscopy revealed an anterior chamber with mild cellularity in both eyes. Intraocular pressure was 65 mmHg in the OD and 60 mmHg in the OS. Fundoscopy revealed total excavation of the optic disc in the OD; details could not be observed in the OS because of vitreitis (Figure 1A and B).

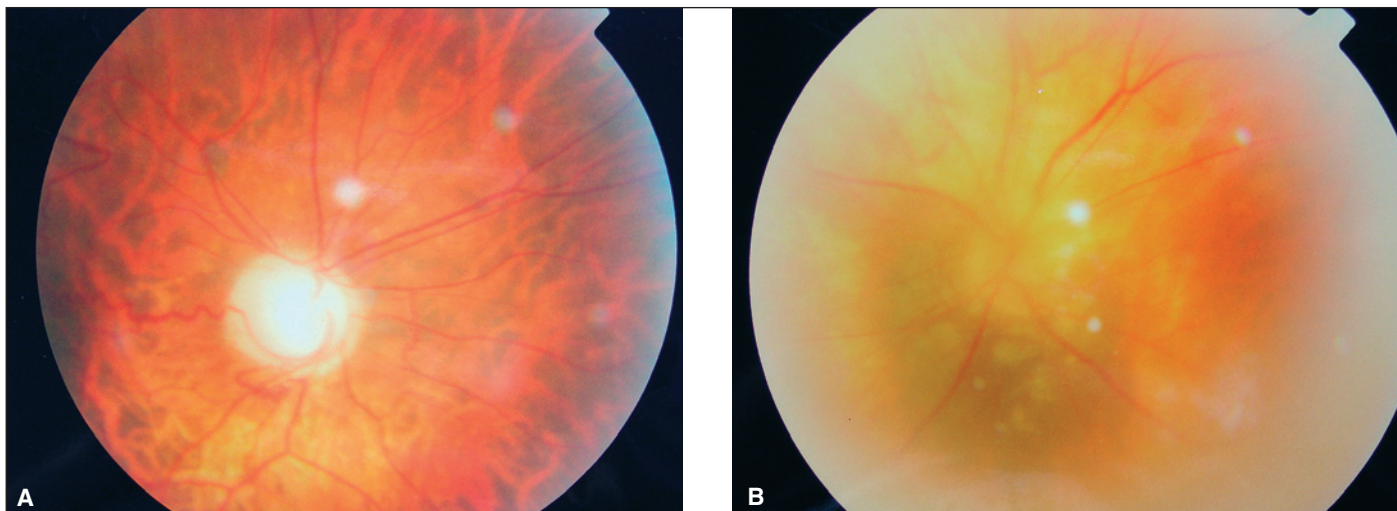


Figure 1 - A: Fundus photography of the right eye showing total excavation of the optic disc; B: Fundus photography of the left eye showing vitreitis and small yellowish lesions surrounding the optic disc

Cultures of OS aqueous humor were positive for *Aspergillus niger*. Material obtained from those cultures was inoculated into the posterior segment of a rabbit eye, with growth and isolation of the same agent (Figure 2).

Limbic base trabeculectomy was performed in the OS without untoward events. During the investigation of the causes of immunodeficiency, HIV-1 antibodies were detected in two different examinations. Radiographic and serologic evaluation and blood culture for fungi were negative. No additional examinations or specific treatment could be performed because the patient did not return for the scheduled visits.

DISCUSSION

In most cases of systemic *Aspergillus* involvement the patients present some type of immunodepression and, among

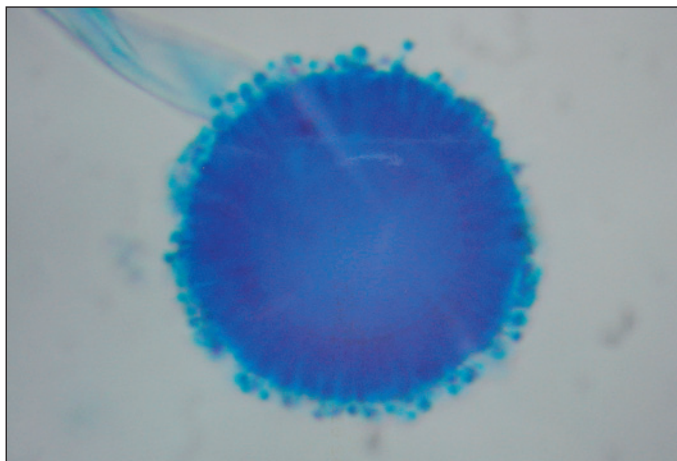


Figure 2 - Microphotography of lactophenol cotton blue stain showing the presence of *Aspergillus niger* from the vitreous of an inoculated rabbit (400x)

HIV-infected patients, those with T CD₄⁺ counts < 50/mm are at higher risk to suffer aspergillosis⁽¹⁾.

Aspergillus endophthalmitis is usually related to systemic or local dissemination, as observed in injection drug users⁽⁴⁾ and in immunosuppressed subjects⁽⁵⁻⁶⁾ or after cataract surgery⁽²⁾. In the present case, no primary foci of hematogenic dissemination were detected, and the patient had no history of surgical procedures.

Since in the present case, as also reported in the literature⁽⁶⁾, there were no confirming signs of the use of drugs, we may raise the hypothesis of endogenous endophthalmitis from a rare site, perhaps with already resolved infection.

The *Aspergillus* hyphae are observed in the slide, but only culture can determine and confirm the species⁽¹⁾. In the present case, the agent was isolated after inoculation in experimental animals, thus completing the Koch postulate.

Although the association of glaucoma and endogenous *Aspergillus* endophthalmitis reported here in an HIV-positive patient is a rare occurrence, the search for fungal agents even in the absence of primary foci is of great relevance in clinical and laboratory terms.

RESUMO

Endoftalmite por *Aspergillus* é geralmente relacionada à disseminação local ou sistêmica do agente em indivíduos imunocomprometidos. Os autores relatam um caso raro de glaucoma bilateral grave secundário a uma infecção intra-ocular por *Aspergillus niger*, na ausência de qualquer foco detectável de aspergilose em paciente HIV-positivo. Foram afastados sinais e antecedentes de uso de drogas injetáveis e o agente foi isolado após inoculação em animais experimentais. Este caso demonstra que a endoftalmite por *Aspergillus* deve ser considerada em pacientes HIV-positivos não-usuários de drogas injetáveis, mesmo na ausência de aspergilose sistêmica.

Descritores: *Aspergillus niger*/isolamento & purificação; Endoftalmite/complicações; Glaucoma/etiologia; Infecções oculares fúngicas; HIV; Hospedeiro imunocomprometido; Relatos de casos [tipo de publicação]

REFERENCES

1. Bennett JE. Aspergilose. In: Fauci AS, Braunwald E, Isselbacher KJ, Martin WJB, Kasper DL, Hauser SL, et al, editores. Harrison Medicina Interna. 14a ed. Rio de Janeiro: McGraw – Hill Interamericana do Brasil; 1998. p.1238-9.

2. Brar GS, Ram J, Kaushik S, Chakraborti A, Dogra MR, Gupta A. *Aspergillus niger* endophthalmitis after cataract surgery. J Cataract Refract Surg. 2002;28(10):1882-3.

3. Feman SS, Nichols JC, Chung SM, Theobald TA. Endophthalmitis in patients with disseminated fungal disease. Trans Am Ophthalmol Soc. 2002;100:67-70; discussion 71-1.

4. Kim RW, Juzych MS, Elliott D. Ocular manifestations of injection drug use. Infect Dis Clin North Am. 2002;16(3):607-22.

5. Hara KS, Ryu JH, Lie JT, Roberts GD. Disseminated *Aspergillus terreus* infection in immunocompromised hosts. Mayo Clin Proc. 1989;64(7):770-5.

6. Machado O de O, Gonçalves R, Fernandes EM, Campos WR, Orefice F, Curi AL. Bilateral *Aspergillus* endophthalmitis in a patient with chronic lymphocytic leukaemia. Br J Ophthalmol. 2003;87(11):1429-30.

XXVII Congresso do Hospital São Geraldo

02 a 04 de Novembro de 2006
Centro de Convenções do Ouro Minas Palace Hotel
Belo Horizonte - MG

INFORMAÇÕES

Tel./Fax: (31) 3291-9899

E-mail: hsgeraldo@consulteventos.com.br

Home page: www.hospitalsaogeraldo.com.br