

# Diseases, conditions, and drugs associated with cicatricial ectropion

## Doenças, condições e drogas associadas ao ectrópio cicatricial

Júlia D. Rossetto<sup>1</sup>, Carolina P. B. Gracitelli<sup>1</sup>, Tammy H. Osaki<sup>1</sup>, Midori H. Osaki<sup>1</sup>

1. Departamento de Oftalmologia e Ciências Visuais, Divisão de Cirurgia Plástica Ocular, Universidade Federal de São Paulo, São Paulo, Brasil.

**ABSTRACT** | Cicatricial ectropion may be a consequence of certain systemic diseases as well as the result of drug use. Our goal here was to research the different causes of this condition as reported in the literature, including more recently suspected etiologies. A detailed PubMed literature search indicated many different etiologies were associated with cicatricial ectropion development, from severe cases of systemic diseases, such as ichthyosis and lupus erythematosus, to reversible scenarios secondary to anti-glaucomatous drug use. More recently reported connections include periorbital necrotizing fasciitis, frontal osteomyelitis, and antineoplastic agents. Indeed, cicatricial ectropion may be highly symptomatic; being able to determine its real etiology is imperative to managing patients properly. In this investigation, we felt that an explicitly multidisciplinary approach was essential, especially for cases associated with systemic conditions.

**Keywords:** Ectropion/diagnosis; Ectropion/chemically induced; Eyelids/abnormalities; Cicatrix

**RESUMO** | O ectrópio cicatricial pode ser uma consequência de certas doenças sistêmicas, bem como o resultado do uso de drogas. Nosso objetivo aqui foi pesquisar as diferentes causas desta condição, conforme relatado na literatura, incluindo mais recentemente suspeitas de etiologias. Uma pesquisa bibliográfica detalhada do PubMed indicou que muitas etiologias diferentes estavam associadas ao desenvolvimento do ectrópio cicatricial, desde casos graves de doenças sistêmicas, como ictiose e lúpus eritematoso, até cenários reversíveis secundários ao uso de drogas antiglaucomatosas. Conexões relatadas mais recentemente incluem fascíte necrosante periorbitária, osteomielite frontal e

agentes antineoplásicos. De fato, o ectrópio cicatricial pode ser altamente sintomático; ser capaz de determinar sua etiologia real é imperativo para o manejo adequado dos pacientes. Nesta investigação, sentimos que uma abordagem explicitamente multidisciplinar era essencial, especialmente para casos associados a doenças sistêmicas.

**Descritores:** Ectrópio/diagnóstico; Ectrópio/induzido quimicamente; Pálpebras/anormalidades; Cicatriz

### INTRODUCTION

Ectropion, the most frequent eyelid malposition<sup>(1,2)</sup>, is an eyelid margin eversion, most commonly of the inferior eyelid. Its incidence and prevalence are unknown<sup>(1,2)</sup>, but it can be classified in accordance with the pathophysiology and the onset time in congenital or acquired (involuntary, paralytic, cicatricial or mechanical) cases<sup>(1,2)</sup>.

A recent report on cicatricial ectropion demographics in 145 patients requiring full-thickness skin grafts showed a mean age of 75, 70% male, and 90% Caucasian (self-reported)<sup>(3)</sup>. For 35% of these cases, the cause was unknown; however, another 35% had a previous transcutaneous lower eyelid blepharoplasty, 20% had a surgical history of lower eyelid or midface reconstruction after Mohs surgery, and 10% had experienced some type of earlier trauma<sup>(3)</sup>.

Cicatricial ectropion is characterized by a vertical shortening of the eyelid, due either to loss of skin elasticity or a lack of tissue in the anterior lamella. Factors that could cause these changes are remarkably diverse and include trauma, burns, actinic skin changes (Figure 1), medications, and blepharoplasty complications<sup>(2,4)</sup>. Recent publications also present a remarkable diversity of new possible causes, such as osteonecrosis secondary to treatment with bisphosphonate, periorbital necrotizing fasciitis, blastomyces dermatitidis, frontal bone osteomyelitis, generalized eruptive keratoacanthomas of the Grzybowski type, and other similar pathologies<sup>(5-11)</sup>.

Submitted for publication: August 16, 2018

Accepted for publication: December 14, 2018

**Funding:** No specific financial support was available for this study.

**Disclosure of potential conflicts of interest:** None of the authors have any potential conflicts of interest to disclose.

**Corresponding author:** Júlia D. Rossetto

Universidade Federal de São Paulo. Departamento de Oftalmologia e Ciências Visuais  
Rua Botucatu, 822, 2º andar - São Paulo, SP - 04023-062 - Brazil  
E-mail: julia\_rossetto@hotmail.com

 This content is licensed under a Creative Commons Attribution 4.0 International License.

This study reviews unusual cicatricial ectropion causes reported in recent years, to help bring attention to possible new etiologies. It is also productive to inform other medical specialties about the diagnosis of early ocular symptoms related to systemic diseases to better facilitate prevention and early treatment for the patients involved.

To this end, an extensive literature search was performed using MEDLINE (via Ovid), EMBASE (via Ovid), and LILACS (Latin American and Caribbean Health Science Literature) via the Virtual Health Library. The search included the following terms (MeSH descriptors): “cicatricial ectropion,” alone and combined with “causes,” and “systemic disease.” Numerous studies about cicatricial ectropion treatment were generally excluded from the search. Our intention was to provide a broader differential diagnosis, so major reviews, as well as small case reports, were included, and no publication time frame was established. Finally, 79 articles were selected, addressing common pathologies as well as rare conditions, with publication dates ranging from 1953 to 2017. Only studies in the English language were included in this review.

## Systemic diseases with cutaneous involvement

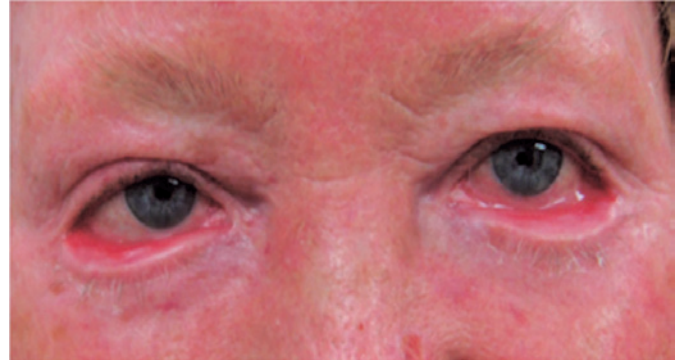
### Ichthyosis

Ichthyosis is a group of inherited skin disorders defined by abnormal keratinization or cornification<sup>(12)</sup> that can be subdivided into ichthyosis vulgaris, epidermolytic hyperkeratosis (autosomal dominant), X-linked ichthyosis, and lamellar ichthyosis (autosomal recessive). The first association between ichthyosis and ectropion dates from 1934<sup>(13)</sup>; since then, this has been the most commonly described eyelid alteration associated with the disease<sup>(13,14)</sup>. Although its association with lamellar ichthyosis is well known, ectropion has also been described in an adult patient with X-linked ichthyosis<sup>(15)</sup>.

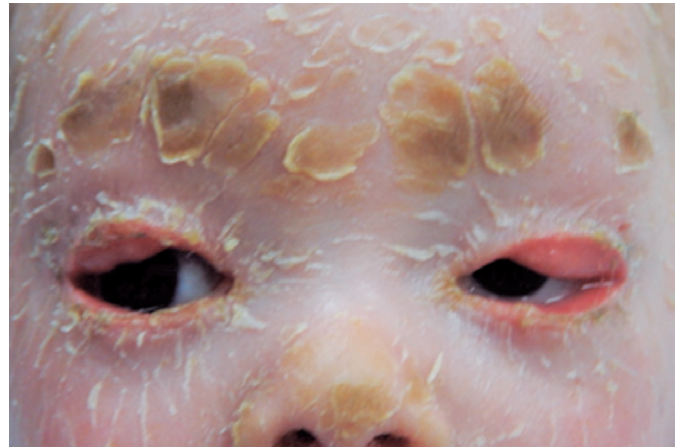Lamellar ichthyosis has an estimated incidence of 1:250,000 to 300,000<sup>(16)</sup>. It presents with a defective skin desquamation that leads to keratin scales of the total body surface, excessive dryness, and hard contracture, which prevents eyelid closure and leads to ectropion (Figure 2). The incidence of cicatricial ectropion in these patients varies between 45 to 80%<sup>(17)</sup>. Other common ocular signs include chronic conjunctivitis and exposure, keratitis with corneal ulceration, and even bilateral spontaneous corneal perforation<sup>(18)</sup>.

Conservative treatment can be sufficient in mild cases<sup>(19)</sup>, but surgical correction with a skin graft is

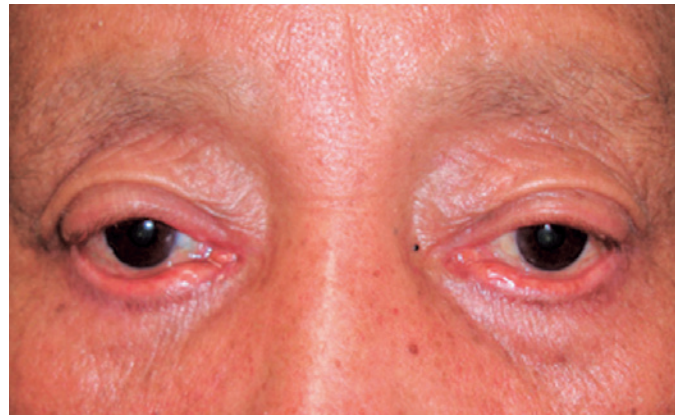
usually required for symptomatic relief. Bilateral severe cicatricial ectropion, lagophthalmos, and corneal exposure occur in patients with a variety of extensive skin diseases. Successful treatments described include a penile foreskin graft in children with total skin invol-



**Figure 1.** Cicatricial ectropion in a female patient with actinic skin changes.



**Figure 2.** Child presenting with ichthyosis and cicatricial ectropion (upper and lower lids).



**Figure 3.** Female patient with psoriatic arthritis presenting with lower lid cicatricial ectropion.

vement except for the prepuce<sup>(17,20)</sup>, and a post auricular skin allograft from the mother in a six-month-old female without a healthy donor site. No postoperative immunosuppression was needed in the latter case<sup>(21)</sup>. Because of widespread skin involvement and life-long duration of the disease, graft contraction commonly occurs, and repeated surgical treatment can be required over the long-term.

#### Psoriatic arthritis

Psoriatic arthritis (PsA) is a chronic condition belonging to the well-known spondyloarthritis complex. It is related to the inflammation of synovial tissue, entheses, and the skin, and frequently presents negative for rheumatoid factor<sup>(22)</sup>. PsA has a heterogeneous clinical presentation; the major features are spondylitis, inflammatory neck pain, thoracic inflammatory pain, and axial symptoms. Unfortunately, its epidemiology is difficult to determined due to the lack of universally accepted diagnostic criteria<sup>(23)</sup>.

Ocular manifestations of this disease seem to be more common in male patients during its exacerbation phases, and are preceded by cutaneous manifestations<sup>(24)</sup>. Conjunctivitis is the most common lesion, followed by iritis, episcleritis, and keratoconjunctivitis sicca<sup>(25)</sup>. The eyelids can be affected by chronic blepharitis and tear film alterations, which can lead to madarosis, trichiasis, loss of lid tissue, and ectropion<sup>(24)</sup> (Figure 3). Our literature review<sup>(26)</sup> revealed that various ophthalmic PsA complications can affect different ocular structures, but remain generally undiagnosed. Gracitelli et al.<sup>(27)</sup> described a symptomatic, bilateral cicatricial ectropion in a patient diagnosed with PsA who was treated with a retroauricular skin graft, became stable, and achieved a resolution of symptoms at one-year follow-up. Because of the disease's systemic, long-term characteristics, symptom recurrence and a repeated need for surgery can be expected.

#### Lupus Erythematosus

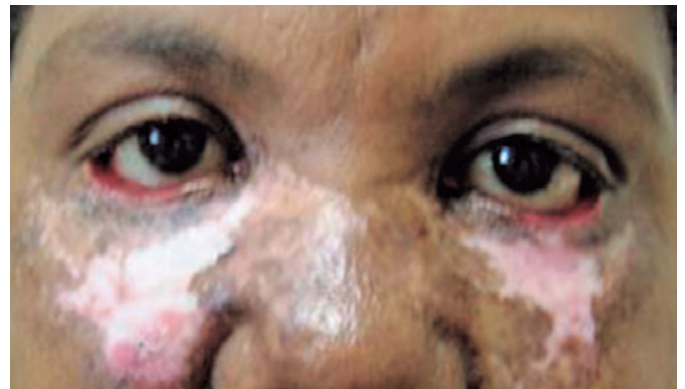Lupus erythematosus (LE) is a chronic skin disease generally classified into six different types: discoid, profundus, chilblain, annular-polycyclic, papulosquamous, and acute<sup>(28)</sup>. The discoid type of LE (DLE) accounts for 50 to 85% of chronic cutaneous LE, which is 2 to 3 times more prevalent than systemic LE (17 to 48/100,000)<sup>(29)</sup>. It is characterized by raised, erythematous skin lesions, more frequently in areas exposed to sunlight, and predominantly affects females (two females: one male) between 20 and 40 years old<sup>(29)</sup>.

DLE's ophthalmologic features were previously reported as the only manifestation of the disease in rare cases, and include violaceous discoloration, periorbital edema, hypertrophic and verrucous lesions, chronic blepharoconjunctivitis, madarosis, lid scarring, trichiasis, ectropion (Figure 4), and entropion, as well as stromal keratitis<sup>(30-35)</sup>. Erythematous plaques of the lower eyelids, which may be associated with conjunctival hyperemia and scarring, had a reported incidence of 6% in patients with chronic cutaneous LE<sup>(36)</sup>.

Cicatricial ectropion may appear as a consequence of a long-term misdiagnosis of DLE in the presence of chronic eyelid lesions and may require surgical repair<sup>(37)</sup>. In light of these numerous presentations, DLE must be considered in the differential diagnosis of refractory chronic blepharoconjunctivitis, eczema, contact dermatitis, and psoriasis<sup>(34,35,38)</sup>.

#### Generalized Eruptive Keratoacanthomas of the Grzybowski type

Grzybowski generalized eruptive keratoacanthoma is a rare, idiopathic disease affecting the skin and mucosal tissues. It is generally an adult-onset and nonfamilial condition, presenting as multiple, small, umbilicated, keratinous, pruritic, and painful papules that heal and leaves deep scars, which have been histologically identified as keratoacanthomas<sup>(39,40)</sup>. The course of the disease is chronic, and it presents with major facial involvement that can lead to ectropion<sup>(11,39,41)</sup>. Rath et al.<sup>(39)</sup> presented a case of a 41-year-old woman diagnosed with this disease who complained of epiphora and blurred vision secondary to cicatricial ectropion. Clinical treatment with lubricants and triamcinolone injections in both



**Figure 4.** Female patient with discoid lupus erythematosus presenting with plaques in the lower lids and cicatricial ectropion.

lower eyelids, as suggested by the dermatologist, failed to treat the ectropion, and a surgical approach with a full-thickness skin graft was performed. The donor skin came from the dorsum of her foot, which was the only healthy-appearing skin of her body. Due to the long-term course of the disease and absence of viable healthy tissue, multiple surgical ectropion corrections are expected, and patients should be warned of this reality in advance<sup>(11,39,41)</sup>.

### Other systemic diseases

#### Tangier disease

This is a rare autosomal recessive disorder caused by a defect in cholesterol metabolism. Affected individuals typically have low plasma levels of cholesterol, mildly elevated triglycerides, and cholesterol ester deposits in tissues such as the conjunctiva, lymph nodes, liver, spleen, skin, and cardiac valves<sup>(42)</sup>.

Tangier's clinical signs include corneal clouding, splenomegaly, lymphadenopathy, and peripheral neuropathy. Ocular abnormalities were reported in 41.2% of Tangier patients, and the most frequent symptom was corneal infiltration (64.3%), followed by orbicular muscle weakness (28.6%) and ectropion (21.4%). One case of bilateral cicatricial ectropion of lower eyelids has also been found<sup>(43)</sup>. Since lid disorder (orbicular weakness and ectropion) might be present prior to corneal infiltration, early recognition and treatment could prevent or materially delay visual loss caused by corneal damage<sup>(43)</sup>.

#### Pyoderma Gangrenosum

This is a chronic dermatosis with a remarkably unknown etiology. It is rare and often associated with systemic inflammatory diseases, which manifests through painful ulcerative skin lesions with rapid progression and is characterized by a deep ulcer with erythematous surrounding skin. In one recent case, cicatricial ectropion was described as the clinical presentation of a periocular pyoderma gangrenosum in a 90-year-old patient. A nearly complete tarsorrhaphy was needed to achieve ocular symptom relief, and skin lesion control was achieved with topical steroid therapy<sup>(44)</sup>.

### Infectious diseases

#### Fungal infections

Paracoccidioidomycosis (PCM) and North American blastomycosis (NAB) are infectious diseases caused by fungi (*Paracoccidioides brasiliensis* and *Blastomyces*

dermatidis). The contagion occurs through inhaling spores into an initial pulmonary condition that is frequent. Cutaneous disease is the most common extrapulmonary involvement.

PCM occurs in Latin America, and although eyelid involvement is infrequent, it can be an isolated manifestation of the disease, with an estimated prevalence of 2.5%<sup>(45,46)</sup>. Madarosis was reported as an early finding, and isolated active lesions were only distinguishable from squamous cell carcinoma on biopsy<sup>(45)</sup>. Other PCM ophthalmologic features include conjunctival lesions, granulomatous uveitis, third cranial nerve palsy, and endophthalmitis<sup>(47-49)</sup>.

After treatment, the lesions heal by fibrosis, leading to cicatricial changes ranging from entropion and/or ectropion to a complete destruction of the lid anatomy, which requires surgical intervention<sup>(45)</sup>.

PCM is a severe and fatal infection if not treated, making early diagnosis imperative, especially in unusual presentations such as an isolated eyelid lesion.

NAB occurs in North America, where the skin manifestation has a predilection for the face and other exposed areas<sup>(50)</sup>. The typical skin lesion is elevated, verrucous, crusted, and varicolored, with a serpiginous border and tends to heal centrally<sup>(51)</sup>.

Eyelid lesions occur in less than 2% of NAB cases, and they can be mistaken for a chalazion, basal, or squamous cell carcinoma. These alternative lesions can be a manifestation of the disease in rare cases<sup>(7)</sup>, and can also instigate severe oculo-facial sequelae<sup>(8,52,53)</sup>. Progressive ectropion, as a consequence of the cicatricial resolution of the lesions, has been reported<sup>(9,53)</sup>. Surgical treatment with skin grafts is usually required, but delaying the procedure until fungal infection clearance and resolution of the scarring process is recommended unless severe exposure is present<sup>(53)</sup>.

Other reported NAB ocular involvement includes conjunctival lesions and optic nerve infection<sup>(54,55)</sup>.

#### Periorbital necrotizing fasciitis

Necrotizing fasciitis (NF) is a subcutaneous soft tissue and underlying fascia infection that can be life-threatening when it infiltrates vital structures, ultimately leading to organ failure. It is a rare condition that begins with painful cellulitis, evolves rapidly to necrosis of the soft tissue, and can be classified into two categories depending on the microorganisms involved: type 1-polymicrobial, more common in immunosuppressed patients, and type 2-group A *Streptococcus*<sup>(56)</sup>.

NF rarely involves the facial and neck regions, and even less frequently the periorbital area<sup>(56)</sup>. However, periorbital NF affects more adults than children, and signs vary from mild presentations, such as localized edema and tenderness, to severe features such as blistering and necrosis. Due to the anatomical eyelid characteristics of thin skin and lack of subcutaneous fat, the infection can become noticeable early and rapidly evolve to necrosis<sup>(6)</sup>. Even in mild presentations, distinguishing between NF and periorbital cellulitis is imperative, and treatment, such as intravenous antibiotics and surgical debridement, should be initiated promptly to avoid devastating consequences such as blindness, meningitis, and death<sup>(57)</sup>.

Reconstruction of cicatricial ectropion, lagophthalmos, or even eyelid loss is frequently required after resolution of an NF infection<sup>(6,58)</sup>. Full-skin grafts are usually needed, and repeated procedures should be expected.

#### Frontal osteomyelitis

This is a rare condition, usually a consequence of frontal sinusitis, head trauma, a complication of sinus surgery, or hematogenous spread<sup>(10)</sup>. It presents with forehead fluctuant swelling (“Potts puffy tumor”), usually accompanied by pain and fever, and can lead to intracranial complications such as subperiosteal abscess<sup>(59)</sup>.

Bandyopadhyay et al.<sup>(10)</sup> described a case of a seven-year-old boy who presented with painless cicatricial ectropion of the left upper eyelid with no history of trauma, surgery, infection, or medication use. His physical exam was unremarkable except for the presence of left superior cicatricial ectropion with adherence to the underlying frontal bone and a small sinus with purulent discharge. The patient was diagnosed with chronic skull osteomyelitis and treated with antibiotics and neurosurgery to remove the necrotic bone and drainage of the purulent material.

Although cicatricial ectropion presented as frontal osteomyelitis is extremely rare, a delay in diagnosis and treatment can be life-threatening.

#### Chromomycosis

Chromomycosis is a persistent, subcutaneous mycosis that occurs in tropical climates, largely affecting the lower limbs, and is associated with skin trauma caused by contact with materials found in nature. *Fonsecaea pedrosoi* is the organism most commonly isolated in this context and it is, unfortunately, often resistant to medical therapy, such as Itraconazole<sup>®</sup> and Amphotericin B<sup>®</sup>.

Rios et al.<sup>(60)</sup>, reported on a 50-year-old Brazilian male rural worker, with a history of shoulder trauma, 30 years before presentation, which had progressed to a severe bilateral cicatricial ectropion. His injury did not improve spontaneously or with unspecified ointments, but instead evolved slowly and continuously. Ten years after the trauma, the patient sought dermatological treatment. A diagnosis of *Fonsecaea pedrosoi* was confirmed by biopsy, and treatment was initiated. He had only a partial response to systemic treatment with Itraconazole<sup>®</sup>, Amphotericin B<sup>®</sup>, and Terbinafine<sup>®</sup> and underwent a skin graft combined with a tarsal strip procedure in both eyes due to the risk of eye perforation.

Managing this etiology is challenging, especially due to the fungus' characteristic resistance to treatment options and to the medications' toxicity. When there is facial involvement with cicatricial ectropion, early surgical intervention may be needed to avoid permanent vision loss<sup>(60)</sup>.

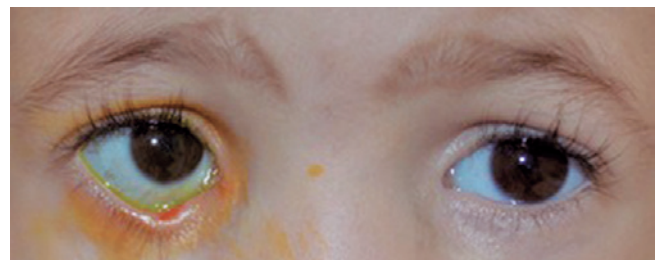#### Other inflammatory/infectious diseases

Dacryocystitis, an inflammation of the lacrimal sac, is frequently related to an ipsilateral nasolacrimal duct obstruction. The most frequent etiological agents are *Staphylococcus aureus*, B-hemolytic *Streptococcus* and *Pneumococcus*, and *Haemophilus influenzae* in children, and *Staphylococcus epidermidis*, *Staphylococcus aureus*, *Streptococcus pneumoniae* as well as *Pseudomonas aeruginosa* in adults. Treatment options include antibiotics, abscess drainage, and dacryocystorhinotomy. Complications include fistula formation, orbital cellulitis, meningitis, cavernous sinus thrombosis and cicatricial ectropion (Figure 5).

#### Medication and other treatment modalities

##### Antineoplastic agents

Periocular toxicity is frequently associated with systemic chemotherapy<sup>(61,62)</sup>. An example suspect is cetuximab,



**Figure 5.** Cicatricial ectropion in the right lower eyelid in a child after three episodes of ipsilateral dacryocystitis.

a monoclonal antibody that binds the epidermal growth factor of cancer and normal epidermal cells to prevent cell-signaling pathways. This agent is beneficial in metastatic colorectal cancer treatment but is commonly associated with cutaneous toxicities<sup>(63)</sup>. Periocular features related to cetuximab toxicity include trichomegaly<sup>(64)</sup>, madarosis, and cicatricial ectropion<sup>(63)</sup>.

In one study, cicatricial ectropion presented as periorbital discomfort, foreign-body sensation, and epiphora one week after treatment began, followed by severe eyelid crusting, intermittent bleeding, and eyelash loss<sup>(63)</sup>. The medication was discontinued due to the lack of systemic response, and the periorbital features resolved six weeks later along with the regrowth of eyelashes and residual hyperpigmentation.

A similar periocular reaction has been observed in connection with the use of erlotinib. It is a second-line, antineoplastic agent used to treat neoplasms, such as non-small-cell lung cancer, since its mechanism involves inhibiting the EGFR receptor. Periocular changes associated with erlotinib include trichomegaly<sup>(61)</sup>, eyelid inflammation, and ectropion<sup>(65,66)</sup>. Signs and symptoms begin within one to six weeks after treatment, persist even with decreased medication doses, and resolve three to six weeks after treatment suspension<sup>(65,66)</sup>. Surgical treatment of the ectropion should be avoided unless the side effects become unbearable and medication cannot be discontinued<sup>(65)</sup>.

Fluorouracil (5-Fluorouracil) is a fluorinated pyrimidine used against several common neoplasms, such as colon and breast cancer. Its ocular side effects have been reported as canalicular obstruction, nasolacrimal sac scarring and ectropion; ectropion was associated with both topical and systemic treatments<sup>(67-70)</sup>. The ectropion was successfully treated with dexamethasone ointment during chemotherapy in one report but recurred when the ointment was discontinued<sup>(70)</sup>; in other reports, patients required surgical repair<sup>(69,71)</sup>.

### Other medications

Bisphosphonates are mainly used due to their ability to induce osteoclastic apoptosis. They are used to treat osteoporosis, Paget's disease, bone metastases, and multiple myeloma. Malik et al.<sup>(5)</sup> reported a case of a 63-year-old male with multiple myeloma who presented with lower eyelid cicatricial ectropion, secondary to bisphosphonate-induced maxillary osteonecrosis. The medication was discontinued, and no further signs of lid malposition were observed.

Topical drug-induced ectropion is mostly associated with anti-glaucoma agents<sup>(72)</sup>. Cicatricial ectropion was associated with cicatricial changes in the anterior lamella after chronic exposure to the medication in susceptible individuals. The most common agent was dorzolamide, followed by brimonidine. Most ectropion cases resolved after discontinuing the medication, and two of the 13 patients in this study underwent successful surgical correction<sup>(72)</sup>. Therefore, topical drug-induced ectropion should not initially be treated with surgery<sup>(73)</sup>.

### Radiotherapy

Radiation therapy may lead to soft tissue contraction, muscular atrophy, and skin dystrophy. When performed as a treatment for orbital and periorbital tumors or inflammatory diseases, it shortens the anterior lamella of the eyelids and leads to cicatricial ectropion<sup>(1)</sup>. Correcting this condition is challenging due to surrounding tissue distortion. The most serious sequelae associated with radiotherapy are corneal exposure and asymmetry compared to the contralateral lid<sup>(1)</sup>.

### Chemical facial peeling

Chemical facial peeling is an anti-aging therapy applied in an attempt to improve skin appearance by reducing wrinkle depth and pigmented lesions. Wojno et al.<sup>(74)</sup> present a case of a 72-year-old female who developed cicatricial ectropion after chemical facial peeling, which was successfully corrected with surgery.

### Lid surgery

Cicatricial ectropion as a complication of lower blepharoplasty (excessive removal of skin) is not uncommon (Figures 6 and 7). Some cases resolve spontaneously after a few weeks; however, others require surgical correction.

Cicatricial ectropion may occur after excising lesions followed by primary closure or more complex eyelid reconstruction. Its incidence following tumor excision of the lower eyelid has been reported to vary between 2.5 to 7%, and 14.2% after a full-thickness skin graft<sup>(75)</sup>. Larger diameter wounds, especially those greater than 21 mm, were more likely to result in ectropion. These wounds were usually more related to malignant lesions. Other factors contributing to ectropion development include graft contraction and infection<sup>(75)</sup>.

Consecutive ectropion can be present after surgical entropion correction. It is commonly related to cicatricial contraction of the anterior lamella and buckling of

the tarsal plate<sup>(76)</sup>. Contributing factors to ectropion are preexisting horizontal eyelid laxity, improper placement of averting sutures during the entropion correction, and extensive postoperative scarring related to poor hemostasis during the surgery<sup>(76)</sup>. The ectropion is reported to be noticeable about one to two months after the procedure<sup>(76)</sup>. Correcting horizontal eyelid laxity during entropion treatment and more conservative surgeries may be advisable to avoid such complications.

#### Orbital trauma

Cicatricial ectropion may appear as a consequence of orbital fractures and their repair. In a retrospective analysis of floor fractures<sup>(77)</sup>, the most common approach mid-lower eyelid incision. Nineteen percent presented postoperative complications, of which 2.6% were related to ectropion. A higher ectropion risk was associated with subsidiary orbital access and multiple operations by the same approach.

#### Facial burns

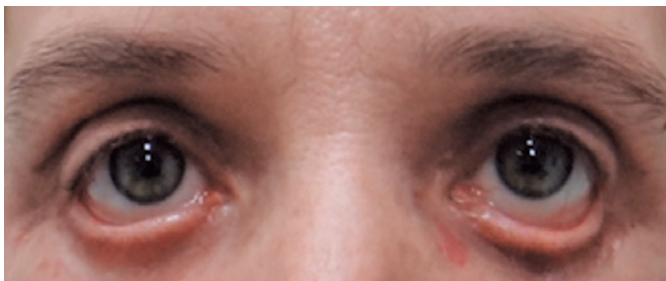
Ophthalmological features are reported to be present in 7.5 to 15% of burn admissions, and cicatricial ectropion was the most common periocular complication of facial burns<sup>(78)</sup>. The ectropion diagnosis is usually made

between 20 and 45 days post-burn. Early excision of necrotic tissue and grafting of the eyelids are recommended to attempt ocular surface protection<sup>(79)</sup>.

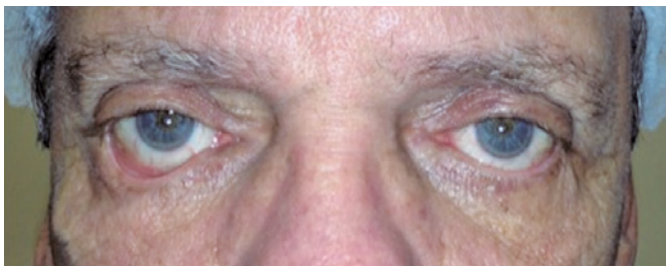Compiling and summarizing the main diseases, conditions, and drugs associated with cicatricial ectropion allows us to approach each etiology holistically and better elucidate the fundamental pathophysiology's involved. Careful anamneses that take into account family history of cutaneous or rheumatic diseases, recent changes to, or discontinuation of, topical or systemic medications, and potential infectious agent exposures associated with certain geographical origins can help optimize medical management for patients. A comprehensive physical examination, not restricted to the periorbital region, is also essential. Most importantly, recognizing atypical manifestations and knowing the diverse diagnostic possibilities are imperative to avoid missing the opportunity to establish early intervention in diseases that, despite primarily presenting as periorbital injuries, can be lethal if not identified.

#### REFERENCES

1. Tarallo M, Rizzo MI, Monarca C, Fanelli B, Parisi P, Scuderi N. Optimal care for eyelid contraction after radiotherapy: case report and literature review. *J Oral Maxillofac Surg.* 2012;70(10):2459-65.
2. Bedran EG, Pereira MV, Bernardes TF. Ectropion. *Semin Ophthalmol.* 2010;25(3):59-65.
3. Ehrlich MS, Richard MJ, Woodward JA. Demographic characteristics of patients requiring full-thickness skin grafts for cicatricial ectropion at Duke Eye Center from 2000 to 2010. *Ophthalm Plast Reconstr Surg.* 2012;28(6):476-7.
4. Vallabhanath P, Carter SR. Ectropion and entropion. *Curr Opin Ophthalmol.* 2000;11(5):345-51.
5. Malik R, Fernando BS, Laitt RD, Leatherbarrow B. Bisphosphonate-induced osteonecrosis of the maxilla presenting as a cicatricial ectropion. *Orbit.* 2014;33(5):369-71.
6. Lazzeri D, Lazzeri S, Figus M, Tascini C, Bocci G, Colizzi L, et al. Periorbital necrotising fasciitis. *Br J Ophthalmol.* 2010;94(12):1577-85.
7. Phelps PO, Seagrave Z, Williams KM. Blastomycosis in the Eyelid of a Native Chicagoan. *Ophthalmology.* 2015;122(5):1015.
8. Bartley GB. Blastomycosis of the eyelid. *Ophthalmology.* 1995;102(12):2020-3.
9. Barr CC, Gamel JW. Blastomycosis of the eyelid. *Arch Ophthalmol.* 1986;104(1):96-7.
10. Bandyopadhyay R, Chatterjee A, Banerjee S, Bandyopadhyay SK, Mondol A. Frontal osteomyelitis presenting as upper eyelid ectropion: A cautionary tale. *Saudi J Ophthalmol.* 2015;29(3):238-41.
11. Consigli JE, González ME, Morsino R, Guidi A, Chappuis JM, Papa M, et al. Generalized eruptive keratoacanthoma (Grzybowski variant). *Br J Dermatol.* 2000;142(4):800-3.
12. Novice FM, Buredorf WH, Esterly NB. *Handbook of genetic skin disorders.* Philadelphia: Saunders; 1994.
13. Jay B, Blach RK, Wells RS. Ocular manifestations of ichthyosis. *Br J Ophthalmol.* 1968;52(3):217-26.



**Figure 6.** Cicatricial ectropion following lower blepharoplasty in a female patient.



**Figure 7.** Cicatricial ectropion following lower blepharoplasty in a male patient.

14. Sever RJ, Frost P, Weinstein G. Eye changes in ichthyosis. *JAMA*. 1968;206(10):2283-6.
15. Adenis JP, Saint-Blancat P. [Cicatricial ectropion and ichthyosis. A propos of 4 cases]. *J Fr Ophthalmol*. 1992;15(5):349-56. French.
16. Cruz AA, Menezes FA, Chaves R, Pinto Coelho R, Velasco EF, Kikuta H. Eyelid abnormalities in lamellar ichthyoses. *Ophthalmology*. 2000;107(10):1895-8.
17. Uthoff D, Gorney M, Teichmann C. Cicatricial ectropion in ichthyosis: a novel approach to treatment. *Ophthalm Plast Reconstr Surg*. 1994; 10(2):92-5.
18. Cinar Y, Selcuk CT, Cingu AK, Turkcu FM, Yuksel H, Yildirim A, et al. Spontaneous bilateral corneal perforation in a patient with ichthyosis. *Int Ophthalmol*. 2014;34(4):919-21.
19. Menke TB, Moschner S, Joachimmeyer E, Ahrens P, Geerling G. [Congenital ectropion in ichthyosis congenita mitis and gravis]. *Ophthalmologie*. 2006;103(5):410-5. German.
20. Hoşal BM, Abbasoğlu OE, Gürsel E. Surgical treatment of cicatricial ectropion in lamellar ichthyosis. *Orbit*. 1999;19(1):37-40.
21. Das S, Honavar SG, Dhepe N, Naik MN. Maternal skin allograft for cicatricial ectropion in congenital ichthyosis. *Ophthalm Plast Reconstr Surg*. 2010;26(1):42-3.
22. Moll JM, Wright V. Psoriatic arthritis. *Semin Arthritis Rheum*. 1973; 3(1):55-78.
23. Liu JT, Yeh HM, Liu SY, Chen KT. Psoriatic arthritis: Epidemiology, diagnosis, and treatment. *World J Orthop*. 2014;5(4):537-43.
24. Kaldeck R. Ocular psoriasis; clinical review of eleven cases and some comments on treatment. *AMA Arch Derm Syphilol*. 1953; 68(1):44-9.
25. Lambert JR, Wright V. Eye inflammation in psoriatic arthritis. *Ann Rheum Dis*. 1976;35(4):354-6.
26. Rehal B, Modjtahedi BS, Morse LS, Schwab IR, Maibach HI. Ocular psoriasis. *J Am Acad Dermatol*. 2011;65(6):1202-12.
27. Gracitelli CP, Osaki TH, Valdrighi NY, Viana GA, Osaki MH. Cicatricial ectropion secondary to psoriatic arthritis. *Case Rep Ophthalmol Med*. 2015;2015:315465.
28. Gilliam JN, Sontheimer RD. Distinctive cutaneous subsets in the spectrum of lupus erythematosus. *J Am Acad Dermatol*. 1981; 4(4):471-5.
29. Patel P, Werth V. Cutaneous lupus erythematosus: a review. *Dermatol Clin*. 2002;20(3):373-85. v.
30. Huey C, Jakobiec FA, Iwamoto T, Kennedy R, Farmer ER, Green WR. Discoid lupus erythematosus of the eyelids. *Ophthalmology*. 1983;90(12):1389-98.
31. Donzis PB, Insler MS, Buntin DM, Gately LE. Discoid lupus erythematosus involving the eyelids. *Am J Ophthalmol*. 1984;98(1):32-6.
32. Tosti A, Tosti G, Giovannini A. Discoid lupus erythematosus solely involving the eyelids: report of three cases. *J Am Acad Dermatol*. 1987;16(6):1259-60.
33. Panse I, Cordoliani F, Rybojad M, Rivet J, Lebbé C, Morel P. [Discoid lupus erythematosus involving the eyelids: 4 cases]. *Ann Dermatol Venereol*. 2004 Jan;131(1 Pt 1):58-60. French.
34. Acharya N, Pineda R 2nd, Uy HS, Foster CS. Discoid lupus erythematosus masquerading as chronic blepharoconjunctivitis. *Ophthalmology*. 2005;112(5):e19-23.
35. Selva D, Chen CS, James CL, Huilgol SC. Discoid lupus erythematosus presenting as madarosis. *Am J Ophthalmol*. 2003;136(3):545-6.
36. Burge SM, Frith PA, Juniper RP, Wojnarowska F. Mucosal involvement in systemic and chronic cutaneous lupus erythematosus. *Br J Dermatol*. 1989;121(6):727-41.
37. Kopsachilis N, Tsaousis KT, Tourtas T, Tsinopoulos IT. Severe chronic blepharitis and scarring ectropion associated with discoid lupus erythematosus. *Clin Exp Optom*. 2013;96(1):124-5.
38. Ena P, Pinna A, Carta F. Discoid lupus erythematosus of the eyelids associated with staphylococcal blepharitis and Meibomian gland dysfunction. *Clin Exp Dermatol*. 2006;31(1):77-9.
39. Rath S, Cowan BJ, Dolman PJ. Cicatricial ectropion in grzybowski type of multiple eruptive keratoacanthomas. *Ophthalm Plast Reconstr Surg*. 2014;30(2):e42-3.
40. Feldman RJ, Maize JC. Multiple keratoacanthomas in a young woman: report of a case emphasizing medical management and a review of the spectrum of multiple keratoacanthomas. *Int J Dermatol*. 2007;46(1):77-9.
41. Mittelviefhaus H. Cicatricial ectropion in progressive skin diseases. *Orbit*. 2001;20(2):91-9.
42. Schaefer EJ, Kay LL, Zech LA, Brewer HB Jr. Tangier disease. High density lipoprotein deficiency due to defective metabolism of an abnormal apolipoprotein A-i (ApoA-ITangier). *J Clin Invest*. 1982;70(5):934-45.
43. Pressly TA, Scott WJ, Ide CH, Winkler A, Reams GP. Ocular complications of Tangier disease. *Am J Med*. 1987;83(5):991-4.
44. Homer N, Freitag SK. Facial pyoderma gangrenosum presenting with cranial nerve vii palsy and cicatricial ectropion. *Ophthalm Plast Reconstr Surg*. 2017; 33(6):e170.
45. Cruz AA, Zenha F, Silva JT Jr, Martinez R. Eyelid involvement in paracoccidioidomycosis. *Ophthalm Plast Reconstr Surg*. 2004;20(3):212-6.
46. Burnier SV, Sant'Anna AE. Palpebral paracoccidioidomycosis. *Mycopathologia*. 1997;140(1):29-33.
47. Silva MR, Mendes RP, Lastória JC, Barraviera B, Marques SA, Kamegasawa A. Paracoccidioidomycosis: study of six cases with ocular involvement. *Mycopathologia*. 1988;102(2):87-96.
48. Belfort R Jr, Fischman O, de Camargo ZP, Almada A. Paracoccidioidomycosis with palpebral and conjunctival involvement. *Mycopathologia*. 1975;56(1):21-4.
49. Dantas AM, Yamane R, Camara AG. South American blastomycosis: ophthalmic and oculomotor nerve lesions. *Am J Trop Med Hyg*. 1990; 43(4):386-8.
50. Woofler MJ, Cripps DJ, Warner TF. Verrucous plaques on the face. North American blastomycosis. *Arch Dermatol*. 2000;136(4):547-50.
51. Witorsch P, Utz JP. North American blastomycosis: a study of 40 patients. *Medicine (Baltimore)*. 1968;47(3):169-200.
52. Pemberton JD, Vidor I, Sivak-Callcott JA, Bailey NG, Sarwari AR. North American blastomycosis of the eyelid. *Ophthalm Plast Reconstr Surg*. 2009;25(3):230-2.
53. Schmutz JS, Ramey NA, Gauthier GM, Lucarelli MJ. Severe Oculofacial Sequelae of Cutaneous Blastomyces dermatitidis. *Ophthalm Plast Reconstr Surg*. 2016;32(3):e61-2.
54. Slack JW, Hyndiuk RA, Harris GJ, Simons KB. Blastomycosis of the eyelid and conjunctiva. *Ophthalm Plast Reconstr Surg*. 1992; 8(2):143-9.
55. Pariseau B, Lucarelli MJ, Appen RE. Unilateral Blastomyces dermatitidis optic neuropathy case report and systematic literature review. *Ophthalmology*. 2007;114(11):2090-4.
56. Bisno AL, Stevens DL. Streptococcal infections of skin and soft tissues. *N Engl J Med*. 1996;334(4):240-5.
57. Doorenbos-Bot AC, Hooymans JM, Blanksma LJ. Periorbital necrotizing fasciitis due to *Cryptococcus neoformans* in a healthy young man. *Doc Ophthalmol*. 1990;75(3-4):315-20.



58. Khurana S, Pushker N, Naik SS, Changole MD, Ghonsikar V, Bajaj M. Periorbital necrotising fasciitis in infants: presentation and management of six cases. *Trop Doct*. 2015;45(3):188-93.
59. Ibarra S, Aguirrebengoa K, Pomposo I, Bereciartúa E, Montejo M, González de Zárate P. [Osteomyelitis of the frontal bone (Pott's puffy tumor). A report of 5 patients]. *Enferm Infecc Microbiol Clin*. 1999;17(10):489-92.
60. Rios JE, Paiva CB, Paula GM, Figueiredo WR, Arantes JC, Almeida FM, et al. Chromomycosis, an unusual cause of cicatricial ectropion: a case report. *Arq Bras Oftalmol*. 2017;80(1):46-8.
61. Pérez-Soler R, Saltz L. Cutaneous adverse effects with HER1/EGFR-targeted agents: is there a silver lining? *J Clin Oncol*. 2005;23(22):5235-46.
62. Busam KJ, Capodiecì P, Motzer R, Kiehn T, Phelan D, Halpern AC. Cutaneous side-effects in cancer patients treated with the anti-epidermal growth factor receptor antibody C225. *Br J Dermatol*. 2001;144(6):1169-76.
63. Garibaldi DC, Adler RA. Cicatricial ectropion associated with treatment of metastatic colorectal cancer with cetuximab. *Ophthal Plast Reconstr Surg*. 2007;23(1):62-3.
64. Dueland S, Sauer T, Lund-Johansen F, Ostenstad B, Tveit KM. Epidermal growth factor receptor inhibition induces trichomegaly. *Acta Oncol*. 2003;42(4):345-6.
65. Methvin AB, Gausas RE. Newly recognized ocular side effects of erlotinib. *Ophthal Plast Reconstr Surg*. 2007;23(1):63-5.
66. Frankfort BJ, Garibaldi DC. Periocular cutaneous toxicity and cicatricial ectropion: a potential class effect of antineoplastic agents that inhibit EGFR signaling. *Ophthal Plast Reconstr Surg*. 2007;23(6):496-7.
67. Haidak DJ, Hurwitz BS, Yeung KY. Tear-duct fibrosis (dacryostenosis) due to 5-fluorouracil. *Ann Intern Med*. 1978;88(5):657.
68. Galentine P, Sloas H, Hargett N, Cupples HP. Bilateral cicatricial ectropion following topical administration of 5-fluorouracil. *Ann Ophthalmol*. 1981;13(5):575-7.
69. Straus DJ, Mausolf FA, Ellerby RA, McCracken JD. Cicatricial ectropion secondary to 5-fluorouracil therapy. *Med Pediatr Oncol*. 1977;3(1):15-9.
70. Hurwitz BS. Cicatricial ectropion: a complication of systemic fluorouracil. *Arch Ophthalmol*. 1993;111(12):1608-9.
71. Tsui M, Tajirian A. Cicatricial Ectropion with Topical 5% Fluorouracil Cream. *Dermatol Surg*. 2016;42(8):1005-6.
72. Hegde V, Robinson R, Dean F, Mulvihill HA, Ahluwalia H. Drug-induced ectropion: what is best practice? *Ophthalmology*. 2007;114(2):362-6.
73. Aristodemou P, Baer R. Reversible cicatricial ectropion precipitated by topical brimonidine eye drops. *Ophthal Plast Reconstr Surg*. 2008;24(1):57-8.
74. Wojno T, Tenzel RR. Lower eyelid ectropion following chemical face peeling. *Ophthalmic Surg*. 1984;15(7):596-7.
75. Rubin P, Mykula R, Griffiths RW. Ectropion following excision of lower eyelid tumours and full thickness skin graft repair. *Br J Plast Surg*. 2005;58(3):353-60.
76. Cheung D, Sandramouli S. Consecutive ectropion after the Wies procedure. *Ophthal Plast Reconstr Surg*. 2004;20(1):64-8.
77. Gosau M, Schöneich M, Draenert FG, Ettl T, Driemel O, Reichert TE. Retrospective analysis of orbital floor fractures-complications, outcome, and review of literature. *Clin Oral Investig*. 2011;15(3):305-13.
78. Astori IP, Muller MJ, Pegg SP. Cicatricial, postburn ectropion and exposure keratitis. *Burns*. 1998;24(1):64-7.
79. Asch MJ, Moylan JA Jr, Bruck HM, Pruitt BA Jr. Ocular complications associated with burns: review of a five-year experience including 104 patients. *J Trauma*. 1971;11(10):857-61.