

# Use of corneal patch graft to repair scleral or corneoscleral defects<sup>+</sup>

## *Reparação de defeito escleral ou corneoscleral com enxerto corneano*

Maria Cristina Nishiwaki-Dantas<sup>(1)</sup>  
Richard L. Abbott<sup>(2)</sup>  
Paulo Elias Correa Dantas<sup>(3)</sup>

### SUMMARY

Different types of graft materials, such as buccal mucosal membrane, auricular cartilage, conjunctiva, fascia lata, periosteum and dermal autografts, aortic and scleral homografts and synthetic materials have been used in order to repair or reinforce scleral or corneoscleral defects with variable results.

We report patients with a minimum one year follow-up, successfully treated with corneal patch graft. In all cases, the corneal patch graft healed well without any evidence of further melting, infection or rejection. The grafts remained intact and able to support the defect, with a favorable final cosmetic appearance.

Therefore, we emphasize the importance of human donor corneal tissue as an excellent alternative graft material to reinforce or repair scleral or corneoscleral defect.

**Key Words:** Corneal patch graft; Corneoscleral surgery; Perforation; Scleritis.

### INTRODUCTION

Scleral or corneoscleral defects may occur resulting from inflammatory diseases with or without infection, alkali burns, surgery (after pterygium excision, cataract extraction, retinal detachment repair) and ocular trauma<sup>1-3</sup>.

In order to repair or reinforce these defects, different types of graft materials have been used with variable results. Buccal mucosal membrane<sup>4</sup>, auricular cartilage<sup>5</sup>, conjunctiva<sup>2,6</sup>, fascia lata<sup>2,7</sup>, periosteum<sup>2,8</sup> and dermal grafts<sup>1</sup>; aortic<sup>9</sup> and scleral<sup>2,10</sup> homografts and synthetic materials (e.g. Gore-tex)<sup>11</sup> have all been tried.

Corneal patch graft (CPG) has been used with success after excision of epibulbar dermoids or recurrent pterygium and to reinforce peripheral

corneal thinning such as Terrien's marginal degeneration, pellucid marginal degeneration or peripheral corneal perforation<sup>2,6,12</sup>. To our knowledge, it has not been described to repair scleral defects.

We report CPG as an alternative graft material to repair scleral and corneoscleral defects.

### CASE REPORTS

#### Case 1

RCS, a 12 year old boy, had a history of perforating trauma with a pencil to his left eye. The lead corneal foreign body was removed from the inferior cornea deep within the stroma and two 10-0 nylon sutures were placed.

Three days after the injury, he presented a bacterial keratitis in this area.

<sup>+</sup> From Department of Ophthalmology - California Pacific Medical Center (CPMC) - San Francisco, California.

<sup>(1)</sup> Gillingham fellow 1994, Pan American Association of Ophthalmology; Cornea fellow, CPMC; Chefe da Seção de Doenças Externas da Santa Casa de São Paulo.

<sup>(2)</sup> Clinical Professor and Director, Corneal and External Disease Service, CPMC.

<sup>(3)</sup> Corneal fellow, CPMC; Assistente da Seção de Cornea e Doenças Externas da Santa Casa de São Paulo.

**Address correspondence and reprint requests:** M. Cristina Nishiwaki-Dantas - Rua Cardoso de Mello Jr., 60 - Alto de Pinheiros, CEP: 05462-020 - São Paulo, SP - Brasil

This study was supported in part by Pan-American Association of Ophthalmology and Allergan/Brasil.

Culture grew *Streptococcus pneumoniae*. Although the corneal ulcer had been sterilized after 3 days of antibiotic therapy, the cornea continued to melt, involving an area up to approximately the visual axis and the adjacent sclera from 3:30 to 8:30 o'clock position, with evident leaking through this inferior area, plugged with iris adherent to the endothelium. His visual acuity (VA) was 20/200.

The patient was taken to the operating room. The necrotic tissue was removed, preparing the corneoscleral lamellar bed, where a full-thickness CPG was placed and sutured with 10-0 nylon suture. Postoperatively, he was maintained on topical and systemic antibiotics, topical steroids and a therapeutic soft contact lens.

The graft became opaque and thickened with growth of peripheral deep vessels, but no inflamed and firmly adherent to the recipient bed. The remainder of the cornea was clear.

One year after the surgery, the CPG was stable and despite the irregular keratometry, his final VA was 20/40.

### Case 2

MY, a 70 year old Japanese woman, who underwent a cataract extraction with posterior chamber implantation in the right eye, 3 years later developed herpes zoster with corneal involvement, treated with topical decadron. After 1 month, the inflammation did not subside and she was then referred to our office. At that time, the VA was 20/80 in this eye. The cornea presented a superonasal 3x3mm suture abscess and a 2mm hypopyon in the anterior chamber (Figure 1). Culture grew *Staphylococcus aureus* and *Serratia marcescens*. She was treated with fortified topical cefazolin and gentamicin, and after 4 days, the infiltrate was stable and the hypopyon began to clear. Topical steroid was added and the antibiotics were gradually tapered.

The patient returned 1 month later, showing a progressive melting, thin-

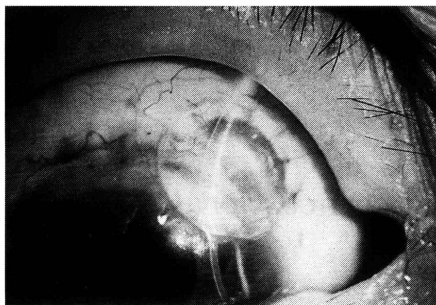


Figure 1: Case 2 - Superonasal corneoscleral suture abscess with progressive melting, thinning and infiltration.

ning and infiltration in the superonasal portion of the cornea and adjacent sclera with impending perforation. The scrapings and cultures were negative. The patient underwent a surgical debridement of the melting tissue and a 7.0mm full-thickness CPG was then placed in the 6.5mm lamellar recipient covered by advancing conjunctiva.

The postoperative course was unremarkable. One year after surgery, the VA was 20/50 in the operated eye with a clear visual axis. Slit-lamp examination revealed an opaque graft with a few superficial neovessels covering the corneoscleral defect, which was completely healed and sealed (Figure 2).

### Case 3

BR, a 68 year old Hispanic woman, underwent a bare sclera procedure for pterygium on the left eye, treated with topical 0.02% mitomycin C four times a day for 14 days and topical steroids.

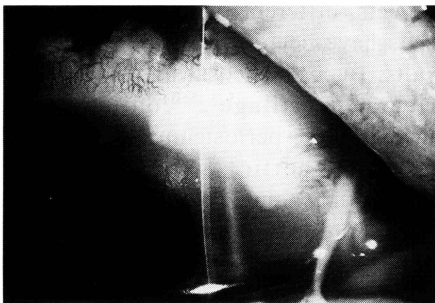


Figure 2: Case 2 - Opaque corneal patch graft with a few superficial vessels covering the corneoscleral defect 1 year after surgery.

She first presented in our office, 8 weeks postoperatively with a progressive thinning of her corneoscleral operative site. The VA was count fingers at 1 ft. Slit-lamp examination revealed a 3+ conjunctival injection with purulent discharge and a corneoscleral defect measuring 6.2x6.1mm with 50% thinning. The tissue in this area appeared necrotic. In addition, a 1.5mm hypopyon was present.

The patient was taken to the operating room where the entire necrotic area was debrided and using a 10.0mm trephine, the margins were outlined, encompassing all of the involved tissue. The lamellar bed was dissected creating a healthy appearing margin 360°. A full-thickness CPG was placed in this bed and sutured with interrupted 10-0 nylon suture. Free hand dissection of the graft measured 10.0mm horizontally by 7.0mm vertically. During the lamellar dissection, multiple cultures were taken and a medial tarsorrhaphy was performed. The patient was maintained on topical antibiotics and steroids, and after 96 hours, all cultures remained negative.

The postoperative course was uneventful and at one year follow-up examination, the CPG was opaque, vascularized and completely incorporated to the lamellar bed. She was comfortable and her VA had improved to 20/200.

JS, a 50 year old man, had a pterygium removed from his right eye, followed by topical 0.02% mitomycin C intra and postoperatively four times a day for approximately 6 days. After 3 months, the referring ophthalmologist noted a non-healing scleral defect in the operated eye and referred him to us for further care. On examination, the VA was 20/20. Slit-lamp examination of the right eye revealed a scleral defect measuring 1.5x3.3mm adjacent to the limbus. This area was surrounded by a 3x4mm avascular conjunctival zone. Within the defect, there was a 2x2mm area of 50% thin-

ning. The nasal cornea adjacent to this area also was thinned to approximately 10%. The remainder of the cornea appeared normal. The anterior chamber was quiet. Nine months following surgery, the sclera showed a continued thinning to 70% depth with further melting and necrosis.

Surgical intervention involved placement of a 5.5mm full-thickness CPG in an area measuring 5.0mm and approximately 70% scleral depth. A free autologous conjunctival graft was placed over the CPG.

The postoperative course was unremarkable. One year after the surgery, the vision was stable at 20/20 in both eyes. The retracted conjunctival graft was partially covering the CPG, which was clear, with early vessel ingrowth. The surrounding sclera appeared stable.

---

#### COMMENTS

---

Patch grafts have been used as tectonic support in the management of scleral or corneoscleral defects.

Previous reports have described the use of different graft materials. Autogenous buccal mucosal membrane in patients with scleromalacia perforans was the first graft successfully recommended by Van der Hoeve in 1934<sup>4</sup>. However, Renard reported failure of this technique, but also reported success, employing autogenous auricular cartilage to repair a small scleral defect<sup>5</sup>.

In 1964, Merz used homologous aortic tissue from human cadaver to successfully reinforce scleral thinning in one case of progressive scleromalacia perforans<sup>9</sup>.

Free autologous conjunctival grafts have been used to prevent pterygium recurrence with excellent results<sup>6</sup>, but they provide little tectonic support when a scleral defect is already present<sup>1</sup>.

Several authors have preferred ho-

mologous sclera as a natural substitute for a scleral defect, however many failures have been reported<sup>2,10</sup>. Problems include the donor sclera becoming either necrotic, sloughing, melting or rejecting.

Autogenous fascia lata<sup>2,7</sup> and periosteum<sup>2,8</sup> have also been used as alternative material for grafts. Both tissues are readily available, durable, easy to work with and not susceptible to immunologic rejection<sup>2,7,8</sup>.

Sclera, fascia lata and periosteum provide adequate support when totally incorporated into the lamellar bed, however, they do not contain epithelium and must be covered by conjunctiva to prevent necrosis. Therefore, dermal graft, a tissue that can survive without being covered by conjunctiva, was used with satisfactory result<sup>1</sup>.

In our 4 patients with a minimum 1 year follow-up, the CPGs survived successfully. The purpose of this report is to emphasize the importance of human donor corneal tissue to reinforce or to repair the weakened or perforated scleral or corneoscleral defect.

In case 1, a traumatic infectious keratitis with extension to the sclera, even after sterilized with the appropriate antibiotics, continued to enlarge. Surgical excision of the necrotic tissue resulted in a large corneoscleral defect that required repair by a CPG. Although the graft became opaque, because of its peripheral location, the final VA was 20/40. In cases 2 and 3, a postoperative infection in the operated area (superior-nasal corneoscleral wound after cataract extraction with posterior chamber implantation in patient 2 and nasal sclera after pterygium excision treated with mitomycin C in patient 3) produced a large corneoscleral defect with progressive melting. In both cases, CPG was able to prevent further scleral melting. The CPG became opaque and fully vascularized, allowing incorporation into the lamellar bed without any associated inflammation.

A significant progressive scleral melting following pterygium excision treated with mitomycin C was successfully managed in case 4. In this case, the CPG has remained relatively clear with only early blood vessel ingrowth, however providing excellent support to the underlying thin scleral bed. The surrounding sclera remained stable without further melting or inflammation.

In all cases, the grafts healed well, without any evidence of further melting, infection or rejection. CPGs have several advantages over other graft materials when used to repair or reinforce scleral or corneoscleral defects.

First, the donor corneal tissue as a patch graft is readily available, since the requirements for patch graft tissue are not as stringent as in penetrating keratoplasty, because optical rehabilitation is not the goal with this procedure. The endothelial cell count, age of the donor, and storage time are not factors in using the tissue. In addition, previous ocular conditions that may preclude its use for penetrating keratoplasty do not exclude its use for CPGing.

Second, CPG has sufficient thickness and strength to seal the perforation or reinforce the weakened tissue, however does not form a bulky irregular surface as does periosteum or fascia lata.

Third, it is easy to handle.

Fourth, the CPG does not necrose when left exposed as often occurs with sclera or fascia lata or periosteum when not covered by conjunctiva.

Fifth, the CPG vascularizes and the resulting reaction does not lead to melting or necrosis of the graft. The graft becomes opaque and vascularized, but remains intact and able to support the defect. Scleral graft does not vascularizes.

Sixth, the CPG has good adhesion to the lamellar recipient bed and the surrounding tissue.

Seventh, the CPG has a favorable

final cosmetic appearance. The graft turns opaque over the scleral portion of the defect, but the corneal portion (in corneoscleral defects) remains fairly clear.

We conclude that CPG may be considered a good option in order to provide tectonic support and preserve the integrity of the eye in cases of impending or actual scleral or corneoscleral perforation.

#### REFERENCES

1. MAURIELLO Jr., J. A. & POKORNY, K. - Use of split-thickness dermal grafts to repair corneal and scleral defects - a study of 10 patients. *Br J Ophthalmol*, 77(6): 327-31, 1993.
2. ROCKWOOD, E. J. & MEISSLER, DM. Scleritis. In Abbott RL. *Surgical intervention in corneal and external diseases*, Grune & Stratton, Orlando, 1987;p.177-87.
3. RAIZMAN MB, de La MAZA MS & FOSTER C.S. - Tectonic keratoplasty for peripheral ulcerative keratitis. *Cornea*, 10(4): 312-6, 1991.
4. VAN der HOEVE J., Scleromalacia perforans. *Arch Ophthalmol*, 11:111-8, 1934.
5. RENARD, G., LELIEVRE, P. & MAZEL J. Scleromalacie perforante. *Bull Mem Soc Fr Ophthalmol*, 66: 243-51, 1953.
6. KENYON, K.R., WAGONER MD & HETTINGER, MT. Conjunctival autograft transplantation for advanced and recurrent pterygium. *Ophthalmology*, 92:1461-70, 1985.
7. TORCHIA, R.T., DUNN R.E. & PEASE P.J. - Fascia lata grafting in scleromalacia perforans. *Am J Ophthalmol*, 66 :705-9, 1968.
8. KOENIG, S.B., SANITATO J.J. & KAUFMAN H.E. - Long-term follow-up study of scleroplasty using autogenous periosteum. *Cornea*, 9(2):139-43, 1990.
9. MERZ, E.H. - Scleral reinforcement with aortic tissue. *Am J Ophthalmol*, 57:766-70, 1964.
10. LEVEL, D. & ABRAMSON A. Necrogranulomatous scleritis treated by onlay. *Br J Ophthalmol*, 56:791-9, 1972.
11. HUANG, W.J., HU F.R. & CHANG S.W. - Clinicopathologic study of Gore-tex patch graft in corneoscleral surgery. *Cornea*, 13(1):82-6, 1994.
12. POIRIER, R.H. & FISH, J.R. Lamellar keratoplasty for recurrent pterygium. *Ophthalmic Surg*, 7:38-41, 1976.



#### **T & M Equipamentos Médicos Ltda.**

Av. Prestes Maia, 241 - 8º andar - salas 815/ 817  
CEP 01031 - 001 - São Paulo - SP

**Responsáveis: Miguel Toro Aguilar e Antônio Paulo Moreira**

#### **REPRESENTANTES EXCLUSIVOS PARA O BRASIL DAS EMPRESAS:**

- **MARCO OPHTHALMIC INC. - USA**  
Lâmpadas de fenda - Refractor - Ceratômetro -  
Lensômetro - Microscópios cirúrgicos - Perímetros  
Yag Laser e Auto perímetro
- **SONOMED INC. - USA**  
Completa linha de ultrassons para oftalmologia:  
Biômetros - Egógrafo e Paquímetro
- **KONAN CAMERA RESEARCH - JAPAN**  
Microscópios cirúrgicos - Microscópio Specular  
e Cell Analysis System
- **EAGLE - Lentes intraoculares**

#### **DISTRIBUIDORES PARA O BRASIL:**

- **HGM - MEDICAL LASER SYSTEMS**  
Completa linha de Argon Laser e Yag Laser
- **NIKON OPHTHALMIC INSTRUMENTS**  
Auto-refrator - Camera retinal - Tonômetro de  
aplanação e demais equipamentos oftalmológicos
- **WELCH ALLYN**  
Retinoscópios - Oftalmoscópios - etc.

#### **NACIONAIS:**

- **XENÔNIO**
- **SIOM**

**NOVOS  
TELEFONES**

**Assistência Técnica:** completa para os equipamentos das empresas representadas.

**Solicite atendimento ou informações:**

São Paulo: T & M - tel.: (011) 229-0304 - Fax: (011) 229-6437

Disk Lentes - tels.: (011) 228-5122 / 228-5448

Ribeirão Preto: Disk lentes - tel.: (016) 635-2943 - Fax: (016) 636-4282