

# Classic homocystinuria and keratoconus: a case report

## Homocistinúria clássica e ceratocone: um relato de caso

Patrícia Ioschpe Gus<sup>1</sup>, Natália Paseto Pilati<sup>2</sup>, Bruna Ossana Schoenardie<sup>2</sup>, Diane Ruschel Marinho<sup>3</sup>

1. Hospital de Clínicas de Porto Alegre, Porto Alegre, RS, Brazil.

2. Universidade Federal do Rio Grande do Sul, Porto Alegre, RS, Brazil.

3. Ophthalmology and Otolaryngology Department, Universidade Federal do Rio Grande do Sul, Porto Alegre, RS, Brazil.

**ABSTRACT** | Homocystinuria is one of a group of genetic disorders called inborn errors of metabolism. It is characterized by a deficiency of the enzyme that converts homocysteine to cystathionine. Keratoconus is an ophthalmologic condition characterized by thinning of the corneal stroma, which causes the cornea to assume a conical shape. There is little information in the scientific literature about the association between keratoconus and homocystinuria. We believe that a collagen cross-linking defect may be the key to understand the connection between these two conditions. This case report describes a 38-year-old male patient with a diagnosis of classical homocystinuria since age 13. At the age of 16, he received a diagnosis of asymmetrical keratoconus when referred for lensectomy with vitrectomy of his left eye. To the best of our knowledge, this is the first report of a patient with simultaneous homocystinuria and keratoconus.

**Keywords:** Keratoconus; Homocystinuria/genetics; Collagen; Corneal stroma

**RESUMO** | Homocistinúria é parte de um grupo de doenças genéticas chamado erros inatos do metabolismo. É caracterizada por uma deficiência da enzima que converte a homocisteína em cistationina. O ceratocone é uma patologia oftalmológica caracterizada pelo afinamento do estroma corneano, o que faz com que a córnea assumam um formato cônico. Há pouca informação na literatura científica sobre a associação entre ceratocone e homocistinúria. Acreditamos que um defeito no cross-linking do colágeno possa ser a chave para entender a conexão entre estas duas condições. Este relato de caso descreve um paciente masculino de 38 anos com diagnóstico de homocistinúria clássica desde os 13 anos. Aos 16 anos, recebeu o diagnóstico de ceratocone assimétrico quando foi encaminhado para len-

sectomia com vitrectomia do olho esquerdo. Até onde sabemos, este é o primeiro relato de um paciente com homocistinúria e ceratocone simultâneos.

**Descritores:** Ceratocone; Homocistinúria/genética; Colágeno; Substância própria

### INTRODUCTION

Homocystinuria is one of a group of genetic disorders called inborn errors of metabolism. It is characterized by a deficiency of the enzyme cystathionine- $\beta$ -synthase, which converts homocysteine to cystathionine. This condition results in an accumulation of homocysteine and methionine, among other metabolites, in the cells and plasma. Homocystinuria is a hereditary disorder with an autosomal recessive inheritance pattern that causes alterations in many parts of the body. The symptoms usually start in the first year of life. The worldwide clinical prevalence of this disease is 1/300,000<sup>(1)</sup>. The main nonophthalmologic alterations in the most common form of homocystinuria are osteoporosis, malar flush, cognitive impairment, and thromboembolic phenomena. In ophthalmology, the main findings are lens subluxation, progressive myopia, and loss of best-corrected visual acuity. Homocystinuria is also associated with microcystic peripheral retinal degeneration, secondary pupillary block glaucoma, retinal detachment, microphthalmos, optic atrophy, retinal arterial occlusions, and band keratopathy<sup>(2)</sup>.

Keratoconus is an ophthalmologic condition characterized by thinning of the corneal stroma, which causes the cornea to assume a conical shape. Abnormal posterior ectasia, abnormal corneal thickness distribution, and clinical noninflammatory corneal thinning are mandatory findings in the diagnosis of keratoconus<sup>(3)</sup>. The prevalence of keratoconus is approximately 1/2000 among the general population. It usually manifests during the

Submitted for publication: December 19, 2017  
Accepted for publication: March 14, 2018

**Funding:** No specific financial support was available for this study.

**Disclosure of potential conflicts of interest:** None of the authors have any potential conflicts of interest to disclose.

**Corresponding author:** Patrícia Ioschpe Gus.

Av. Carlos Gomes, 403/608 - Porto Alegre, RS - 90480-003 - Brazil  
E-mail: patriciaigus@me.com

second decade of life and progresses for approximately 10 years until stabilization. Keratoconus is bilateral and usually asymmetrical and causes irregular astigmatism and myopia. In advanced cases or in those in which the vision cannot be improved with contact lenses, corneal transplantation may be needed.

The case report below describes a patient who was diagnosed with simultaneous homocystinuria and keratoconus. To the best of our knowledge, this is the first such reported case. We believe that these two disorders may be correlated due to alterations in collagen metabolism.

**CASE REPORT**

The patient is a 38-year-old man who received a diagnosis of classical homocystinuria (cystathionine-β-synthase deficiency) at age 13. He was responsive to vitamin B<sub>12</sub>, which he has been taking ever since diagnosis.

At the age of 16, he was referred for lensectomy with vitrectomy of the left eye (OS) due to bilateral subluxated crystalline lenses. The same procedure was performed in the right eye (OD) at the age of 26. No intraocular lens implantation was performed. At this time, he also received a diagnosis of asymmetrical keratoconus. His

visual acuity with glasses was 20/50 with +8.50 sph -2.00 cyl 180 OD and 20/100 with -3.00 sph -3.50 cyl 135 OS. At the last visit, the patient was wearing a soft contact lens in OD (20/50) and a scleral lens in OS (20/40). Corneal topography showed the typical pattern of bilateral keratoconus, which was much more advanced in OS (Figures 1 and 2). The thinnest pachymetric measurements were 544 and 232 μm in OD and OS, respectively. The retinal examination was normal.

**DISCUSSION**

The pathophysiology of keratoconus is believed to be a defect in collagen, which allows for enzymatic degradation and fibrillary slippage, resulting in weakening of the cornea. The association of keratoconus with connective tissue disorders is based partly on reports of association between collagen metabolism disorders and keratoconus. A study of 44 patients with keratoconus showed that 22 of them had hypermobility of the joints<sup>(4)</sup>. Keratoconus has also been described in patients with imperfect osteogenesis, Ehlers-Danlos syndrome, mitral valve prolapse, and other conditions linked to alterations in collagen metabolism. In keratoconic corneas, there are some changes in the proteoglycans, such as a

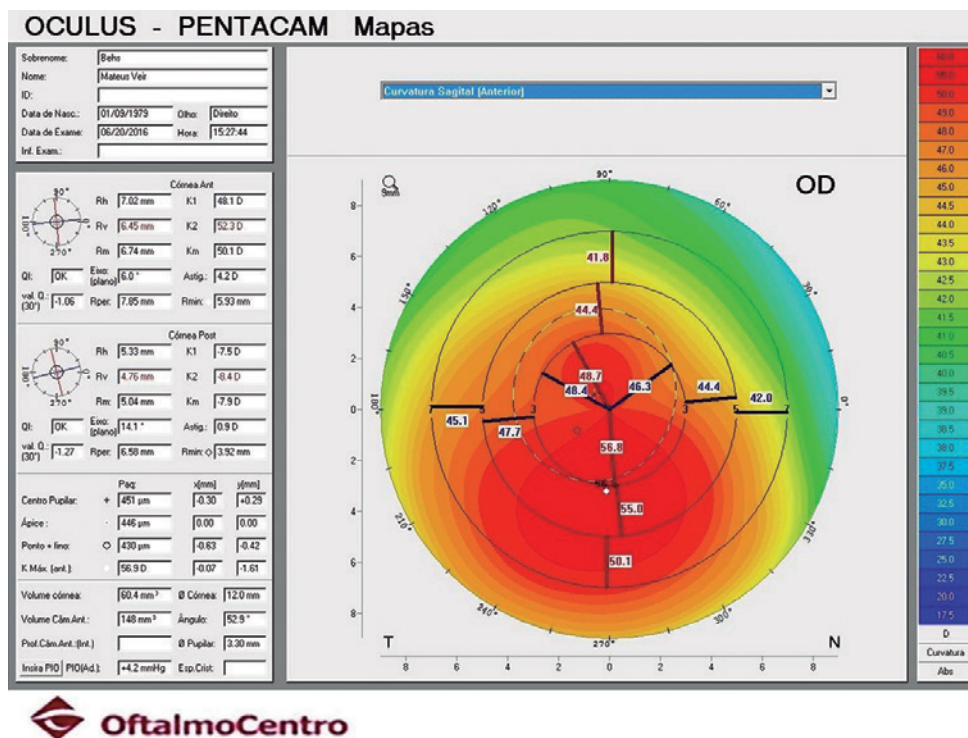


Figure 1. Right eye topography.

