

# Use of the Ishikawa diagram in a case-control analysis to assess the causes of a diffuse lamellar keratitis outbreak

## *Aplicando o diagrama de Ishikawa em uma análise caso-controle para identificar as causas de um surto de ceratite lamelar difusa*

LUIS HENRIQUE LIRA<sup>1</sup>, FLÁVIO E. HIRAI<sup>1</sup>, MARIVALDO OLIVEIRA<sup>2</sup>, WALDIR PORTELLINHA<sup>2</sup>, ELIANE MAYUMI NAKANO<sup>1,2</sup>

### ABSTRACT

**Purpose:** To identify the causes of a diffuse lamellar keratitis (DLK) outbreak using a systematic search tool in a case-control analysis.

**Methods:** An Ishikawa diagram was used to guide physicians to determine the potential risk factors involved in this outbreak. Coherence between the occurrences and each possible cause listed in the diagram was verified, and the total number of eyes at risk was used to calculate the proportion of affected eyes. Multivariate analysis was performed using logistic regression to determine the independent effect of the risk factors, after controlling for confounders and test interactions.

**Results:** All DLK cases were reported in 2007 between June 13 and December 21; during this period, 3,698 procedures were performed. Of the 1,682 flap-related procedures, 204 eyes of 141 individuals presented with DLK. No direct relationship was observed between the occurrence of DLK and the presence of any specific factors; however, flap-lifting enhancements, procedures performed during the morning shift, and non-use of therapeutic contact lenses after the surgery were significantly related to higher occurrence percentages of this condition.

**Conclusions:** The Ishikawa diagram, like most quality tools, is a visualization and knowledge organization tool. This systematization allowed the investigators to thoroughly assess all the possible causes of DLK outbreak. A clear view of the entire surgical logistics permitted even more rigid management of the main factors involved in the process and, as a result, highlighted factors that deserved attention. The case-control analysis on every factor raised by the Ishikawa diagram indicated that the commonly suspected factors such as biofilm contamination of the water reservoir in autoclaves, the air-conditioning filter system, glove powder, microkeratome motor oil, and gentian violet markers were not related to the outbreak.

**Keywords:** Keratitis/epidemiology; Keratomileusis, laser in situ; Corneal injury; Refractive surgical procedure; Cornea

### RESUMO

**Objetivos:** Identificar as causas de um surto de ceratite lamelar difusa (DLK) utilizando uma ferramenta de busca sistemática em uma análise de caso-controle.

**Métodos:** O diagrama de Ishikawa foi usado para orientar os médicos a identificar os potenciais fatores de risco envolvidos neste surto. Coerência entre as ocorrências e cada causa possível listada no diagrama foi verificada. O número total de olhos em risco foi usada para calcular a porcentagem de olhos afetados. A análise multivariada foi realizada por meio de regressão logística para determinar o efeito independente dos fatores de risco, controle de fatores de confusão e interações de teste.

**Resultados:** Todos os casos de ceratite lamelar difusa foram relatados em 2007 entre 13 de junho e 21 de dezembro, durante este tempo foram realizados no total 3.698 procedimentos. De um total de 1.682 procedimentos relacionados a confecção de um flap, 204 olhos de 141 indivíduos apresentaram ceratite lamelar difusa. Não foi observada relação direta entre a ocorrência de ceratite lamelar difusa e a presença de qualquer fator específico; no entanto, procedimentos que incluíam um novo levantamento do flap, procedimentos realizados no turno da manhã, e o não-uso de lentes de contato terapêuticas após a cirurgia foram significativamente relacionados com a ocorrência desta complicação.

**Conclusão:** O diagrama de Ishikawa é uma ferramenta de visualização e organização do conhecimento. Essa sistematização permitiu aos investigadores pesquisar todas as possíveis causas do surto de ceratite lamelar difusa. Uma visão clara de toda a logística cirúrgica permitiu a gestão mais rígida dos principais fatores envolvidos no processo. A análise de caso-controle em relação a cada fatores levantados pelo diagrama indicou que fatores sempre suspeitos, tais como: contaminação do biofilme da água do reservatório das autoclaves, sistema de filtro de ar-condicionado, pó de luva, óleo de motor do microcerátomo e marcador violeta de genciana, não foram relacionados com o surto.

**Descritores:** Ceratite/epidemiologia; Ceratomileuse assistida por excimer laser in situ; Lesões da córnea; Procedimentos cirúrgicos refrativos; Córnea

### INTRODUCTION

As a procedure, laser-assisted in situ keratomileusis (LASIK) is not free of complications. These complications are specifically related to the creation and presence of a corneal flap. Buttonholes, incomplete flaps, free caps, and lacerations that occur during flap creation<sup>(1)</sup>, as well as the postoperative onset of interface folds<sup>(2)</sup>, flap displacement<sup>(3)</sup>, flap delamination<sup>(4)</sup>, epithelial ingrowth<sup>(5)</sup> at the interface, and diffuse lamellar keratitis<sup>(6)</sup> (DLK), remain an area of concern with

respect to LASIK procedures. An early description of DLK referred to it as a sandy deposit of whitish material on the flap's interface; as such, this nonspecific inflammatory condition was first known as "Sands of Sahara Syndrome."

Previous studies have reported that the incidence of DLK varies from 0.67%<sup>(7)</sup> to 0.81%<sup>(8)</sup> and that it may develop in response to primary LASIK, following enhancements without the use of microkeratomes<sup>(9)</sup> or in flap creation using a femtosecond laser<sup>(10)</sup>, mainly

Submitted for publication: October 6, 2016

Accepted for publication: March 12, 2017

<sup>1</sup> Department of Ophthalmology and Visual Sciences, Universidade Federal de São Paulo, São Paulo, SP, Brazil.

<sup>2</sup> Excimer Laser Santa Cruz, São Paulo, SP, Brazil.

**Funding:** No specific financial support was available for this study.

**Disclosure of potential conflicts of interest:** None of the authors have any potential conflict of interest to disclose.

**Corresponding author:** Luis Henrique Lira. Department of Ophthalmology and Visual Sciences, Universidade Federal de São Paulo. Rua Botucatu, 821 - São Paulo, SP - 04023-062 - Brazil  
E-mail: luishlira@hotmail.com

**Approved by the following research ethics committee:** Universidade Federal de São Paulo (CAAE: 46698015.1.0000.5505).

occurring during outbreaks (as was noted in 64% of cases)<sup>(7)</sup>. Because this is a noninfectious condition, many factors have been proposed as causes of DLK and the etiological factors have not always been identified<sup>(11)</sup>.

The Ishikawa diagram, also called a cause-and-effect diagram, Fishbone diagram, or root cause analysis, was invented by Kaoru Ishikawa (1969), who first used the technique in the 1960s. This tool is a diagram that shows the causes of a certain event, and it is considered one of the seven basic tools of quality management. A common application of the Ishikawa diagram is in product design, wherein it is used to identify desirable factors leading to an overall effect. When the fishbone diagram is drafted, one has a complete picture of all possible root causes of the designated problem<sup>(12)</sup>. The purpose of this study was to determine the causes of a DLK outbreak by employing the Ishikawa diagram in a case-control analysis.

**METHODS**

The Ishikawa diagram was adopted for this investigation. The source of DLK outbreak served as the central effect in this visual brainstorming approach. With respect to the possible causes of DLK outbreak, we listed "staff personnel," "materials," "equipment," "instruments," "medications," "solutions," "patients," and "environment" as the primary categories. Subcategories for each major cause can be visualized in figure 1.

All DLK occurrences dated within a period of 15 days before and 15 days after the first and last cases, respectively, were recorded. The percentage of occurrences among the total number of surgeries and the occurrence pattern were established.

Trials were conducted to establish a relationship between the occurrence of DLK and the physician, technician, or room attendant present in the operating theater. Further, we verified the specific microkeratome machine used, the operating room (OR), and the sequence position in the period during which the surgeries were performed for these cases.

The logistic routine of the surgical asepsis of the patient and medical team was also reviewed. Methodical changes of all materials, medications, and solutions used during the surgical procedure (Figure 1) were carried out under careful observation.

Environmental analysis consisted of examining air, workstation surface, and floor samples of the three ORs, material centers, and hand-scrubbing sites. All specimens were forwarded to a specialized

laboratory for analysis. The air conditioner filter and ducts were also cleaned. During the outbreak, 228 different doctors utilized our facilities for surgery; 58 of them had patients with DLK. Finally, an analysis of the air quality and quantification of the particles in the suspension were performed.

A case patient was defined as a patient who developed DLK within 48 h of undergoing a flap-related refractive procedure (i.e., a flap-lift enhancement or myopic or hyperopic LASIK). Cases were ascertained through ophthalmic examination. All individuals who underwent the same procedures on the same dates as the selected cases but did not develop DLK were chosen as controls.

**STATISTICAL ANALYSIS**

The total number of at-risk eyes for developing DLK was used to calculate the proportion of affected eyes. Each individual contributed only one eye in the statistical analysis; for those with both affected eyes, one eye was randomly chosen as a case, and if only one eye was affected, this eye was chosen to be a case. For controls, one eye from each non-affected person was randomly chosen. If only one eye was submitted to surgery during this period, it was chosen as a control.

Chi-square and Fisher's exact tests were performed to compare categorical variables, and *t*-tests were used to compare continuous variables. Multivariate analysis was performed with logistic regression to determine the independent effect of risk factors, and confounders and test interactions were controlled for.

Ethics committee approval was obtained from the Research Ethics Committee of Universidade Federal de São Paulo.

**RESULTS**

**PERIOD OVERVIEW**

All 3,698 procedures that were performed during the study period were classified as either "Flap Involving" or "Non-Flap." A baseline count of the number of surgeries performed during the analysis period was extracted, which spanned from January to June 2007. Of a mean number of 791 procedures per month, 686 (86.7%) involved flaps (68.8%, myopic LASIK; 25.8%, hyperopic LASIK; and 5.5%, flap-lifting enhancements).

The outbreak began on June 13, 2007 and ended on December 21, 2007. During this time, 204 eyes of 141 individuals presented with DLK (12.0%); this was of a total of 1,682 eyes that underwent refractive surgery involving a flap-related procedure.

**DLK DEMOGRAPHICS**

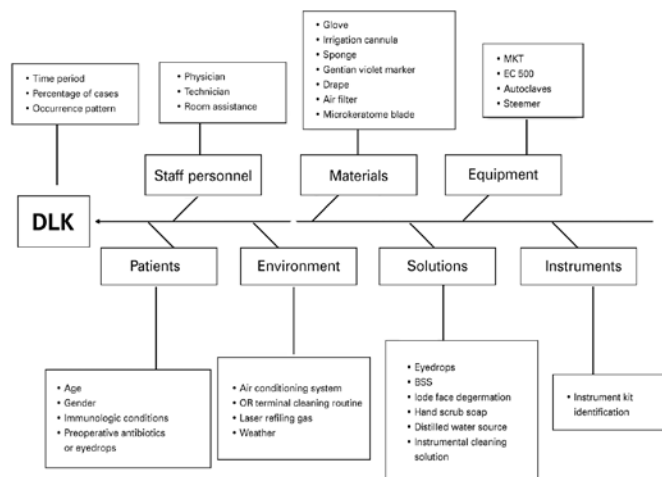
Sixty-two patients presented with bilateral DLK (124 eyes; 7.3%). Among these, 118 eyes (59 patients) had the surgeries performed simultaneously, whereas 6 eyes (3 patients) underwent the operation on different days for each eye.

Eighty patients had monocular DLK. Among these, 26 individuals had both eyes operated simultaneously, 23 underwent the operation on different days for each eye, and 31 had only one eye operated.

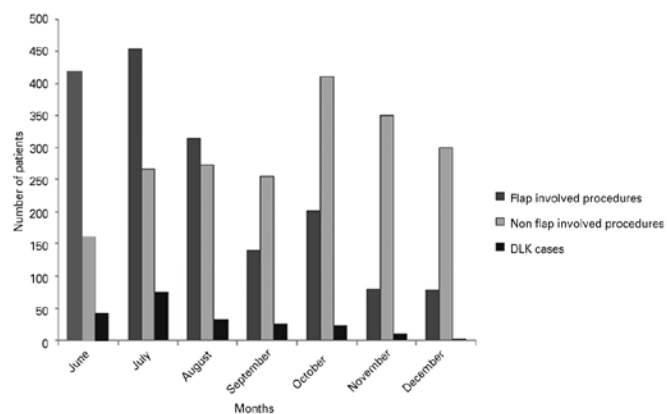
The number of "flap-involving" procedures gradually dropped over the study period; overall, 78 surgeries were performed in December. July experienced a peak in the incidence of DLK cases, and in absolute numbers, there were 74 cases in total in this month (16%). However, during the relative analysis, it was determined that the incidence of DLK cases peaked in September, during which, 25 cases (18%) of the 140 flap-involving surgeries presented with DLK (Graph 1).

The patients' mean age was not statistically different between positive and negative cases for DLK (*p*=0.36). A slightly higher proportion of males was observed among the cases (*p*=0.23). Most surgeries were performed during the evening, and myopic LASIK was the most frequently performed surgery.

Of a total of 1,142 myopic LASIK procedures, DLK occurred in 144 eyes (12%), and of a total of 414 hyperopic LASIK procedures, 31



**Figure 1.** An Ishikawa diagram in which the focus of the analysis was a diffuse lamellar keratitis (DLK) outbreak. All probable causes of the problem are listed according to the major categories that form the spine bones of the "fish."



**Graph 1.** Note the decrease in the number of “flap-involving” procedures over the period of the outbreak, which is in stark contrast to the increase in the numbers of surface treatments that were performed from June to December 2007. Although, in terms of absolute numbers, July showed a peak in the incidence of diffuse lamellar keratitis (DLK), with 74 cases, September yielded the greatest percentage of DLK cases, with 25 cases (18%) of the 140 performed surgeries developing DLK. In the graph, the dark gray columns represent “flap-involving” procedures, the light gray columns represent “non-flap” procedures, and the black columns represent DLK cases.

eyes presented with DLK (7%). Finally, among the 128 flap-lift enhancements, 29 eyes (22%) developed DLK. In one case, DLK occurred in an incomplete keratomileusis, which led to the cessation of laser ablation. No significant difference in the rate of DLK was observed between these two procedures ( $p=0.06$ ). Moreover, flap-lift enhancements were strongly related to DLK occurrence ( $p=0.01$ ). Table 1 shows the results of the multivariate analysis.

Eyes that received flap-lift enhancement were approximately three times more likely to develop DLK than eyes that underwent hyperopic LASIK ( $p=0.001$ ), after adjusting for several confounders [odds ratio (OR): 3.09 (95% confidence interval (CI): 1.58-6.06)].

Individuals who underwent surgery during the morning shift had a 50% greater chance of developing DLK than those who underwent surgery in the evening [OR:1.51 (95% CI: 1.00-2.27)]. The use of contact lenses in the postoperative period diminished the chance of DLK development by 65% [OR: 0.35 (95% CI: 0.14-0.85)] after controlling for confounders. Furthermore, the incidence of DLK was not related to the expertise of the professional who performed the LASIK procedure.

None of the seven Hansatome microkeratomers or the Nidek MK2000 systems contributed to the occurrence of DLK. Similarly, glove use or glove brand, gentian violet corneal markers, hand-scrubbing products, surgical instrument cleaning solutions, facial cleaning solutions, sponge brands, water sources, biofilms in autoclave water reservoirs, intraoperative medications, and solutions did not seem to be related to DLK occurrence.

The fact that there were new occurrences of DLK, irrespective of the systematic and routine changes in the performed surgeries, suggested that there was no relationship between the development of DLK and any of the primary factors, including equipment, materials, instruments, medications, solutions, staff personnel, and environment.

## DISCUSSION

The use of the Ishikawa diagram provided a clear view of the entire surgical logistics and facilitated even more rigid management of the main factors involved in the process and, thus, highlighted factors that deserved attention.

**Table 1.** Odds ratios and 95% confidence intervals of the associations between risk factors and the development of diffuse lamellar keratitis (DLK)

Risk factors	Yes (n=141)	No (n=789)	P-value
Age (years)	34.29 ± 10.6	35.23 ± 11.6	0.360
Sex, male (%)	45.6	40.1	0.230
Period			0.170
Morning	39.7	31.7	
Afternoon	15.6	16.6	
Evening	44.7	51.7	
Procedures			0.002
Enhancements	16.3	9.0	
Myopic LASIK	68.8	64.8	
Hyperopic LASIK	14.9	26.2	
Microkeratome			0.007
Hansatome	72.4	81.1	
Nidek	11.3	10.8	
Flap lifts	16.3	8.1	
Anesthetics			0.110
Anestalcon	78.0	67.4	
Oxinec	18.4	26.5	
Others	3.6	2.4	
Hand scrub solution			0.050
Clorexidine	75.9	67.4	
Dr. Clean	24.1	32.6	
None	13.5	9.8	0.110
Supermax	24.1	19.4	
Polimax	62.4	70.8	
Facial cleaning			0.020
VPPI	21.3	30.2	
Water and soap	23.4	27.2	
Cetrimide	55.3	42.2	
Drape			0.270
70101 SN	41.1	42.2	
70201 SN	26.9	21.5	
Inda 157	12.8	10.9	
Others	19.2	25.4	
Corneal marker			0.018
Yes	93.6	86.5	
Sponge			0.060
Merocel	49.6	63.7	
Excel	41.8	30.1	
Meroalcon	8.6	6.2	
Alcohol rinsing of instruments			0.300
Yes	30.5	26.2	
Tube air filter			0.034
Yes	82.3	73.8	
Water source for hand scrubbing			0.080
Tap	19.9	28.5	
Filtered	49.6	45.9	
Mineral	30.5	24.6	
Premix gas			0.060
Original	82.9	75.7	
Other suppliers	17.1	24.3	
Therapeutic contact lenses			0.004
Yes	6.4	15.2	

Data are presented as the mean ± standard deviation or percentage.

These processes included air drying the surgical instruments and the autoclave reservoirs at the end of each surgical day, rigorously cleaning or discarding all materials in a controlled manner, performing medicine contamination checkups, mindfully introducing any new brands of materials, engaging in environmental control, ensuring patient and staff asepsis, and performing proper sterilization of the surgical instruments and equipment.

The rate of DLK after microkeratome LASIK flap creation has been estimated to be 0.4-7.7%<sup>(13,14)</sup>. In comparison, the rate of DLK after femtosecond LASIK flap creation ranges from 0.4% to 19.4%<sup>(15,16)</sup>. There is increasing interest in understanding this phenomenon. Studies have shown that high laser energy levels and the ensuing photodisruption-induced tissue injury and accumulation of gas bubbles can lead to an increased inflammatory response and DLK<sup>(17-19)</sup>.

Different elements have been attributed as the trigger for inflammation in DLK, including surgical glove powder and silicon; *Sphingomonas paucimobilis*/*Burkholderia pickettii* endotoxins; gonococcal keratoconjunctivitis; toxic chemicals; ophthalmic sponges; recurrent epithelial erosion; cleaning solutions<sup>(20)</sup>; trauma; uveitis; and iritis.

Histological and confocal microscopy findings of the cells recovered from interface scrapings in DLK have shown the presence of lymphocytes, eosinophils, and neutrophils<sup>(21)</sup>. Degenerated cells have also been observed as the inflammatory process progresses. The immunological response during the inflammatory process involves interleukin-8, which may be found in the stromal keratocytes and infiltrating neutrophils<sup>(22)</sup>, thus endorsing the theory that an immune-mediated inflammatory mechanism is involved.

Differential diagnoses of DLK include epithelial ingrowth at the interface, infectious infiltrates, sponge residues, tear film debris, and central toxic keratopathy.

No major consequences are typically seen in the corneas following the resolution of DLK. Neither corneal irregularities nor induced refractive errors are commonly observed; as such, the late resolution results are predictable<sup>(9)</sup>. However, complications associated with untreated and naturally progressing DLK include corneal melting and tissue consumption. Further, a hyperopic shift in the final refraction of eyes after severe DLK has been previously reported<sup>(23)</sup>.

Following the present analysis, the authors concluded that flap-lift enhancement procedures, procedures performed during the morning shift, and discontinuing the use of therapeutic contact lenses immediately after the surgery are highly related to DLK occurrence. Interestingly, commonly suspected factors such as glove powder, ophthalmic sponges, corneal marker pens, cleaning solutions, biofilms in autoclave water reservoirs, and air-conditioning filters, as well as microkeratome engine oil leaks, were not found to be possible causes of the DLK outbreak.

## REFERENCES

- Nakano K, Nakano E, Oliveira M, Portellinha W, Alvarenga L. Intraoperative microkeratome complications in 47,094 laser in situ keratomileusis surgeries. *J Refract Surg.* 2004; 20(5 Suppl):S723-6.
- Knorz MC. Flap and interface complications in LASIK. *Curr Opin Ophthalmol.* 2002; 13(4):242-5.
- Cheng AC, Rao SK, Leung GY, Young AL, Lam DS. Late traumatic flap dislocation after LASIK. *J Refract Surg.* 2006;22(5):500-4.
- Nakano EM, Kuchembuck M, Nakano K, Oliveira M, Alvarenga LS, Portellinha W. [LASIK interface fluid accumulation caused by glaucoma associated with herpetic keratouveitis: case report]. *Arq Bras Oftalmol.* 2007;70(1):165-7. Portuguese.
- Naoumidi I, Papadaki T, Zacharopoulos I, Siganos C, Pallikaris I. Epithelial ingrowth after laser in situ keratomileusis: a histopathologic study in human corneas. *Arch Ophthalmol.* 2003;121(7):950-5.
- Smith RJ, Maloney RK. Diffuse lamellar keratitis. A new syndrome in lamellar refractive surgery. *Ophthalmology.* 1998;105(9):1721-6.
- Bigham M, Ems CL, Holland SP, Buxton J, Patrick D, Marion S, et al. Diffuse lamellar keratitis complicating laser in situ keratomileusis: post-marketing surveillance of an emerging disease in British Columbia, Canada, 2000-2002. *J Cataract Refract Surg.* 2005; 31(12):2340-4.
- Noda-Tsuruya T, Toda I, Asano-Kato N, Hori-Komai Y, Fukumoto T, Tsubota K. Risk factors for development of diffuse lamellar keratitis after laser in situ keratomileusis. *J Refract Surg.* 2004;20(1):72-5.
- Stulting RD, Randedleman JB, Couser JM, Thompson KP. The epidemiology of diffuse lamellar keratitis. *Cornea.* 2004;23(7):680-8.
- Javalov J, Artola A, Vidal MT, Muñoz G, de Rojas V, Alió JL. Severe diffuse lamellar keratitis after femtosecond lamellar keratectomy. *Br J Ophthalmol.* 2007;91(5):699.
- A mysterious tale: the search of the cause of 100+ cases of diffuse lamellar keratitis. *J Refract Surg.* 2002;18(5):551-4. Comment in: *J Refract Surg.* 2004;20(1):85-6.
- Meyeer VR. Measurement uncertainty of liquids chromatographic analyses visualized by Ishikawa diagrams. *J Chromatogr Sci.* 2003;41(8):439-43. Erratum in: *J Chromatogr Sci.* 2003;41(8):439-43.
- Johnson JD, Harissi-Dagher M, Pineda R, Yoo S, Azar DT. Diffuse lamellar keratitis: incidence, associations, outcomes, and a new classification system. *J Cataract Refract Surg.* 2001;27(10):1560-6.
- Thammano P, Rana AN, Talamo JH. Diffuse lamellar keratitis after laser in situ keratomileusis with the Moria LSK-One and Carriazo-Barraquer microkeratomers. *J Cataract Refract Surg.* 2003;29(10):1962-8.
- Gil-Cazorla R, Teus MA, de Benito-Llopis L, Fuentes I. Incidence of diffuse lamellar keratitis after laser in situ keratomileusis associated with the IntraLase 15 kHz femtosecond laser and Moria M2 microkeratome. *J Cataract Refract Surg.* 2008;34(1):28-31.
- Haft P, Yoo SH, Kymionis GD, Ide T, O'Brien TP, Culbertson WW. Complications of LASIK flaps made by the IntraLase 15- and 30-kHz femtosecond lasers. *J Refract Surg.* 2009;25(11):979-84.
- Binder PS. One thousand consecutive IntraLase laser in situ keratomileusis flaps. *J Cataract Refract Surg.* 2006;32(6):962-9.
- Gil-Cazorla R, Teus MA, de Benito-Llopis L, Fuentes I. Incidence of diffuse lamellar keratitis after laser in situ keratomileusis associated with the IntraLase 15 kHz femtosecond laser and Moria M2 microkeratome. *J Cataract Refract Surg.* 2008;34(1):28-31.
- Moshirfar M, Gardiner JP, Schliesser JA, Espandar L, Feiz V, Mifflin MD, et al. Laser in situ keratomileusis flap complications using mechanical microkeratome versus femtosecond laser: retrospective comparison. *J Cataract Refract Surg.* 2010;36(11):1925-33.
- Nakano EM, Nakano K, Oliveira MC, Portellinha W, Simonelli R, Alvarenga LS. Cleaning solutions as a cause of diffuse lamellar keratitis. *J Refract Surg.* 2002;18(3 Suppl):S361-3.
- De Rojas Silva MV, Abalde MJ, Diez-Feijóo E, Yáñez PM, Javalov J, Sánchez-Salorio M. Confocal microscopy and histopathological examination of diffuse lamellar keratitis in an experimental animal model. *J Refract Surg.* 2007;23(3):299-304.
- Asano-Kato N, Toda I, Shimmura S, Noda-Tsuruya T, Fukagawa K, Yoshinaga M, et al. Detection of neutrophils and possible involvement of interleukin-8 in diffuse lamellar keratitis after laser in situ keratomileusis. *J Cataract Refract Surg.* 2003;29(10):1996-2000.
- Dada T, Pangteev MS, Sharma N, Vajpayee RB, Jhanji V, Sethi HS. Hyperopic shift after LASIK induced diffuse lamellar keratitis. *BMC Ophthalmol.* 2006;6:19.