

Contact lens fitting in a patient with Alport syndrome and posterior polymorphous corneal dystrophy: a case report

Adaptação de lentes de contato em paciente com síndrome de Alport e distrofia polimorfa posterior: relato de caso

JULIANA MARIA DA SILVA ROSA¹, MARCELO VICENTE DE ANDRADE SOBRINHO¹, CÉSAR LIPENER¹

ABSTRACT

Alport Syndrome is a hereditary disease that is caused by a gene mutation and affects the production of collagen in basement membranes; this condition causes hemorrhagic nephritis associated with deafness and ocular changes. The X-linked form of this disease is the most common and mainly affects males. Typical ocular findings are dot-and-fleck retinopathy, anterior lenticonus, and posterior polymorphous corneal dystrophy. Some cases involving polymorphous corneal dystrophy and corneal ectasia have been previously described. Here we present a case report of a 33-year-old female with Alport syndrome, posterior polymorphous corneal dystrophy, and irregular astigmatism, whose visual acuity improved with a rigid gas permeable contact lenses.

Keywords: Collagen diseases; Nephritis, hereditary; Corneal dystrophies, hereditary/etiology; Contact lenses

RESUMO

A síndrome de Alport é descrita como uma doença hereditária que afeta um gene relacionado à produção de colágeno das membranas basais causando nefrite hemorrágica associada com surdez e alterações oculares. A forma ligada ao X é a mais comum e afeta principalmente homens. Os achados oculares típicos são retinopatia em ponto-mancha, lenticone anterior e distrofia polimorfa posterior. Alguns casos foram descritos de associação entre a distrofia polimorfa posterior e ectasia corneana. Nós apresentamos um caso de paciente do sexo feminino, 33 anos, diagnóstico de síndrome de Alport, distrofia polimorfa posterior e astigmatismo irregular, que apresenta melhora da acuidade visual após adaptação com lentes de contato rígidas gás permeáveis.

Descritores: Doenças do colágeno; Nefrite hereditária; Distrofias hereditárias da córnea/etiologia; Lentes de contato

INTRODUCTION

Arthur Alport first published his description of a triad of symptoms in a family with hereditary congenital hemorrhagic nephritis, deafness, and ocular changes in 1927. To this day, Alport syndrome may still inevitably leads to end-stage renal disease and the need for renal replacement therapy, starting in young adulthood⁽¹⁾. Alport syndrome has a prevalence of 1 in 5,000, and 85% of patients have the X-linked form, which mainly affects males. The typical ocular associations are a dot-and-fleck retinopathy that occurs in approximately 85% of affected adult males, anterior lenticonus that occurs in approximately 25%, and the rare posterior polymorphous corneal dystrophy (PPCD). The retinopathy and anterior lenticonus do not usually appear during childhood but tend to worsen with time so that the retinal lesions are often present at the onset of renal failure; the anterior lenticonus develops later. The presence of anterior lenticonus or posterior polymorphous corneal dystrophy in any individual is highly suggestive for the diagnosis of Alport syndrome. Additional ocular features described in X-linked Alport syndrome include other corneal dystrophies, microcornea, arcus juvenilis, iris atrophy, cataracts, spontaneous lens rupture, spherophakia, posterior lenticonus, a poor macular reflex, fluorescein angiogram hyperfluorescence, electrooculogram and electroretinogram abnormalities, and retinal pigmentation. All mutations that have been detected to date in X-linked Alport syndrome have affected the COL4A5 gene, which en-

codes the alpha-5 chain of type IV collagen. This protein plays a role in the basement membranes of the glomerulus, cochlea, retina, lens capsule, and cornea, resulting in abnormal ultrastructures⁽²⁾.

CASE REPORT

RCBL, a 33-year-old female, with previously diagnosed Alport syndrome, was referred to the contact lenses sector complaining of poor vision in OU. She had presented chronic renal failure (two kidney transplantations), and had undergone cataract surgery in both eyes one year ago due to anterior lenticonus (Figure 1-3).

Ophthalmological examination denoted bilateral posterior polymorphous dystrophy (PPD), intraocular lenses that were in the bag in both eyes, as well as multiple perimacular changes on funduscopy (dot-and-fleck retinopathy). Her refraction was OD: -7.00 -1.00 @ 180 (VA: 0.30 - LogMAR) and OS: -3.25 -4.00 @ 125 (VA: 0.40 - logMAR). Her corneal topography showed an irregular astigmatism with superior steepening in both eyes (Figure 4).

After comprehensive ophthalmological examination and rigid gas permeable contact lens fitting, we were able to improve her visual acuity to 0.18 in OD and 0.30 in OS (logMAR). The prescribed contact lens had the following parameters:

- OD: Spherical, Base Curve 47.25D/Dioptic power: -6.00 D/Diameter: 9.4 mm.
- OS: Spherical, Base Curve 47.00D/Dioptic power: -4.00 D/Diameter: 9.4 mm.

Submitted for publication: October 27, 2014
Accepted for publication: February 6, 2015

¹ Setor de Lentes de Contato e Refração, Universidade Federal de São Paulo (UNIFESP) - São Paulo, SP - Brazil.

Funding: No specific financial support was available for this study.

Disclosure of potential conflicts of interest: None of the authors have any potential conflict of interest to disclose.

Corresponding author: Juliana Maria da Silva Rosa. Avenida João Carlos Machado, 455/202 - Rio de Janeiro, RJ - 22620-081 - Brazil - E-mail: jumsrosa@gmail.com

Approved by the following research ethics committee: UNIFESP - number 871432.




Figure 1. Anterior lenticonus - picture before cataract surgery.

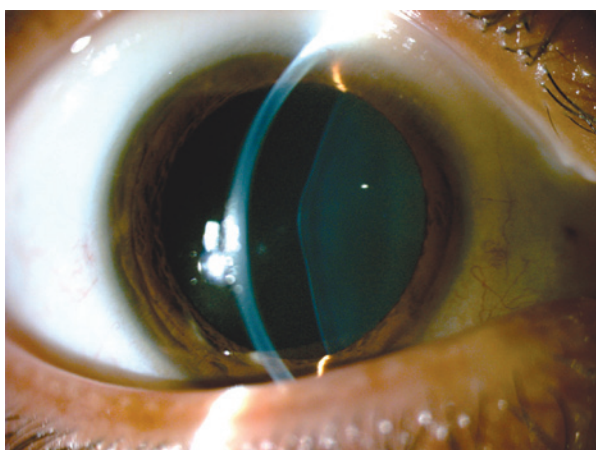


Figure 2. Anterior lenticonus in OD before cataract surgery.

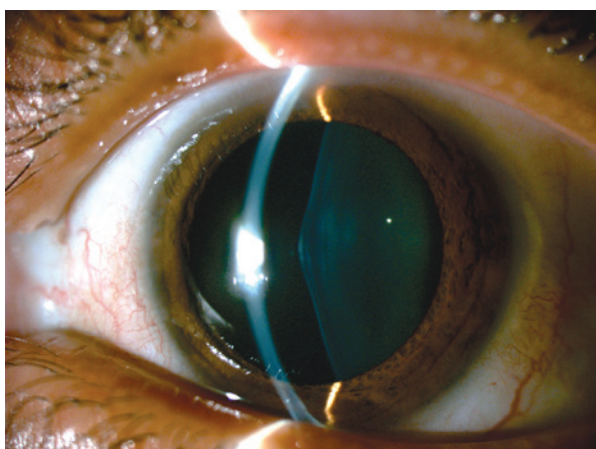


Figure 3. Anterior lenticonus OS - picture before cataract surgery.

DISCUSSION

The main features of Alport Syndrome are kidney failure, hearing loss, and ocular features, such as anterior lenticonus (15%-25% of patients, and may also be associated with cataract), dot-and-fleck re-

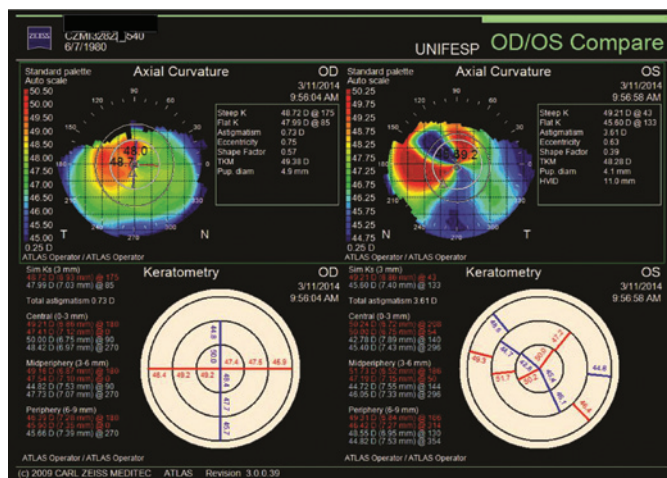


Figure 4. Corneal topography, after cataract surgery, shows irregular astigmatism with superior steepening OU.

tinopathy (85%), and PPCD⁽³⁾. Aldave *et al* suggested that there was a gene (*ZEB1*) involved in keratocyte function that may play a role in both the corneal stromal and endothelial development and function. The identification of abnormally steep corneal curvatures in 37% of all individuals with PPCD and in 86% of affected individuals with PPCD secondary to *ZEB1* mutations confirms this association⁽⁴⁾. Many genetically determined corneal dystrophies can occur in association with keratoconus including PPCD, lattice dystrophy, granular dystrophy, and Fuchs endothelial dystrophy. The association with so many corneal dystrophies and ocular abnormalities implies either a similarity in the underlying genetic defect or a tightly-linked network of interacting proteins, with a final common developmental pathway⁽⁵⁾. PPCD and keratoconus share a potential common area of involvement (the posterior corneal surface, specifically Descemet’s membrane) and/or an underlying commonality for the pathophysiology of corneal dystrophies. A recent paper characterized the cornea in patients with PPCD and demonstrated that the topographic parameters were significantly steeper but had no clinical or topographical evidence of keratoconus. The authors accumulated a cohort of patients who presented between 1982 and 2004 with a mean topographic simulated keratometry reading of 52.21 D, ranging from 46.47 D to 59.86 D, with no slit lamp or topographic findings suggestive of keratoconus⁽⁶⁾. In this particular case, our patient had Alport Syndrome, PPCD, irregular astigmatism with superior steepening in both eyes; however, her visual acuity was improved with rigid gas permeable (RGP) scleral CLs despite other findings.

REFERENCES

1. Kruegel J, Rubel D, Gross O. Alport syndrome-insights from basic and clinical research. *Nat Rev Nephrol.* 2013;9(3):170-8.
2. Colville DJ, Savage J. Alport syndrome. A review of the ocular manifestations. *Ophthalmic Genet.* 1997;18(4):161-73.
3. Xu JM, Zhang SS, Zhang Q, Zhou YM, Zhu CH, Ge J, Wang L. Ocular Manifestations of Alport Syndrome. *Int J Ophthalmol.* 2010;3(2):149-51.
4. Aldave AJ, Ann LB, Frausto RF, Nguyen CK, Yu F, Raber IM. Classification of Posterior Polymorphous Corneal Dystrophy as a Corneal Ectatic Disorder Following Confirmation of Associated Significant Corneal Steepening. *JAMA Ophthalmol.* 2013;131(12):1583-90.
5. Gasset AR, Zimmerman TJ. Posterior polymorphous dystrophy associated with keratoconus. *Am J Ophthalmol.* 1974;78:535-7.
6. Raber IM, Fintelman R, Chhabra S, Ribeiro MP, Eagle RC Jr, Orlin SE. Posterior polymorphous dystrophy associated with nonkeratoconic steep corneal curvatures. *Cornea.* 2011;30:1120-4.