

# Upper lid crease approach for margin rotation in trichomatous cicatricial entropion without external sutures

## *Abordagem via sulco palpebral superior para a rotação marginal no entrópico cicatricial tracomatoso sem o emprego de suturas externas*

ANTONIO AUGUSTO VELASCO E CRUZ<sup>1</sup>, PATRICIA M. S. AKAISHI<sup>1</sup>, MOHAMMED AL-DUFAILEEJ<sup>2</sup>, ALICIA GALINDO-FERREIRO<sup>2,3</sup>

### ABSTRACT

**Purpose:** To describe the use of a lid crease incision for upper eyelid margin rotation in cicatricial entropion combining internal traction on the anterior lamella, tarsotomy, and tarsal overlap without external sutures.

**Methods:** Surgical description: The main steps of the procedure consisted of exposure of the entire tarsal plate up to the eyelashes followed by tarsotomy through the conjunctiva. A double-armed 6.0 polyglactin suture was then passed through the distal tarsal fragment to the marginal section of the orbicularis oculi muscle. As the sutures were tied, the distal tarsus advanced over the marginal section, and traction was exerted on the marginal strip of the orbicularis muscle. There were no bolsters or external knots. The pretarsal skin-muscle flap was closed with a 6.0 plain gut suture.

**Results:** We used this procedure at a tertiary hospital in Saudi Arabia from 2013 to 2014. Sixty upper lids of 40 patients (23 women and 17 men) were operated on, with an age range of 44-99 years [mean  $\pm$  standard deviation (SD) = 70.9  $\pm$  13.01 years]. Bilateral surgery was performed on 21 patients. Follow-up ranged from 1 to 12 months (mean 3.0  $\pm$  2.71 months). Forty percent of the patients (24 lids) had more than 3 months' follow-up. The postoperative lid margin position was good in all cases. Trichiasis (two lashes) was observed in only one patient with unilateral entropion on the medial aspect of the operated lid.

**Conclusions:** The upper lid margin can be effectively rotated through a lid crease incision with internal sutures. The technique combines the main mechanisms of the Wies and Trabut approaches and avoids the use of bolsters or external sutures, which require a second consultation to be removed. Some other lid problems, such as ptosis, retraction, or dermatochalasis, can be concomitantly addressed during the procedure.

**Keywords:** Cicatrix; Entropion/surgery; Eyelids/surgery; Ophthalmologic surgical procedures; Suture techniques

### RESUMO

**Objetivo:** Descrever uma técnica de rotação marginal superior para a correção do entrópico cicatricial combinando incisão via sulco palpebral, tarsotomia e tração na lamela anterior sem o emprego de suturas externas.

**Métodos:** Técnica cirúrgica. Os passos críticos da cirurgia incluem exposição completa da superfície anterior do tarso até a linha dos cílios e tarsotomia horizontal a 3 mm da margem palpebral, produzindo dois segmentos tarsais, marginal e distal. O fragmento distal é avançado sobre o marginal por meio de 3 suturas biagulhadas absorvíveis 6.0 passadas entre a margem do segmento tarsal distal e o músculo orbicular marginal. Dessa maneira, além da superposição tarsal as suturas traçam o orbicular marginal evertendo simultaneamente a margem palpebral e a linha ciliar. Nenhum fio é exteriorizado. O retalho pretarsal miocutâneo era fechado com suturas de catgut 6,0.

**Resultados:** A técnica descrita foi utilizada em hospital terciário na Arábia Saudita, em 2013 e 2014. Sessenta pálpebras superiores de 40 pacientes (23 mulheres e 17 homens) foram operadas. A idade dos pacientes variou de 44 a 99 anos (média = 70,9  $\pm$  13,01 anos). A cirurgia foi bilateral em 21 pacientes. O seguimento variou de 1 a 12 meses (média = 3,0  $\pm$  2,71 meses). Em 24 pálpebras (40%) o seguimento foi superior a 3 meses. A posição da margem palpebral foi considerada boa em todos os casos. Somente 1 paciente com entrópico unilateral apresentou recidiva da triquiase (2 cílios).

**Conclusão:** A margem palpebral de pacientes com entrópico cicatricial pode ser evertida utilizando-se incisão no sulco palpebral e suturas internas. A técnica descrita combina os princípios das cirurgias de Wies e Trabut e tem como principais vantagens incisão cosmética no sulco palpebral e o não uso de suturas externas. Adicionalmente, o acesso pelo sulco palpebral permite a correção de condições associadas, como dermatocálase, ptose ou retração palpebral.

**Descritores:** Cicatriz; Entrópico/cirurgia; Pálpebras/cirurgia; Procedimentos cirúrgicos oftalmológicos; Técnicas de sutura

### INTRODUCTION

Upper eyelid cicatricial entropion (UCE) is a common cause of trichiasis and results from any pathological process that causes scarring of the tarsal plate and consequent inward rotation of the lid margin. In several regions of the Middle East and Africa, trachoma is the most common cause of UCE<sup>(1)</sup>. In Western countries, UCE is usually due to a variety of other causes including chronic blepharitis, previous surgeries, pemphigus, chronic use of topical glaucoma medications, and anophthalmic socket contraction<sup>(2)</sup>.

As trachoma is an ancient blinding disease, there is a considerable amount of literature on surgical techniques for correcting trichomatous UCE that can be traced back to ancient Chinese medical texts<sup>(3)</sup>. Most modern procedures are based on a horizontal tarsotomy across the entire tarsal plate and the use of sutures to evert the lid margin. In English literature, a majority of authors advocate different variants of the anterior approach described by Wies during the 1950s for spastic entropion of the lower eyelid<sup>(4,5)</sup> as well as that used by Ballen<sup>(6)</sup> to rotate the upper lid margin in cases of cicatricial entropion. These surgeries

Submitted for publication: April 23, 2015

Accepted for publication: October 1, 2015

<sup>1</sup> Department of Ophthalmology, Otorhinolaryngology and Head and Neck Surgery, Escola de Medicina de Ribeirão Preto, Universidade de São Paulo (USP), São Paulo, SP, Brazil.

<sup>2</sup> King Khaled Eye Specialist Hospital, Riyadh, Saudi Arabia.

<sup>3</sup> Department of Ophthalmology, Complejo Asistencial Palencia, Palencia, Spain.

**Funding:** No specific financial support was available for this study.

**Disclosure of potential conflicts of interest:** None of the authors have any potential conflict of interest to disclose.

**Corresponding author:** Antonio Augusto V. Cruz. Department of Ophthalmology, School of Medicine of Ribeirão Preto, University of São Paulo. Av. Bandeirantes, 3.900, Ribeirão Preto, SP, Brazil  
E-mail: aavacruz.fmrp@gmail.com

**Approved by the following research ethics committee:** King Khaled Eye Specialist, Project number: RP 1374-R.

were typically performed with a through-and-through incision placed 3 mm or 4 mm from the lid margin<sup>(7-11)</sup>. In African French-speaking countries and many places in the Middle East, the posterior approach as described by Trabut is the preferred procedure<sup>(12)</sup>.

We describe a lid crease approach with internal absorbable sutures for upper lid margin rotation in cases of trachomatous cicatricial entropion. This is a versatile procedure that does not require any bolsters and allows the surgeon to correct the lid margin position and simultaneously address a variety of associated conditions with a single external incision.

## METHODS

Institutional Review Board approval was obtained for a chart review of patients with trachomatous cicatricial entropion who underwent surgery at the King Khaled Eye Specialist Hospital (Riyadh, Saudi Arabia). All surgeries were performed with an anterior approach and a lid crease incision. Preoperatively, all lids had trachomatous entropion, trichiasis, and the typical conjunctivalization of the margin with the mucocutaneous junction overriding the meibomian gland line. Other signs of trachoma, such as Herbert's pits and corneal pannus, were also present in all cases.

Postoperatively, the position of the lid margins was assessed with slit-lamp biomicroscopy in all patients. The degree of rotation was categorized as good only when the meibomian gland orifices were clearly visible without any traction on the anterior lamella and were not covered by the tarsal conjunctiva. Any residual trichiasis or inward displacement of the meibomian gland line was registered as unsatisfactory.

## SURGICAL TECHNIQUE

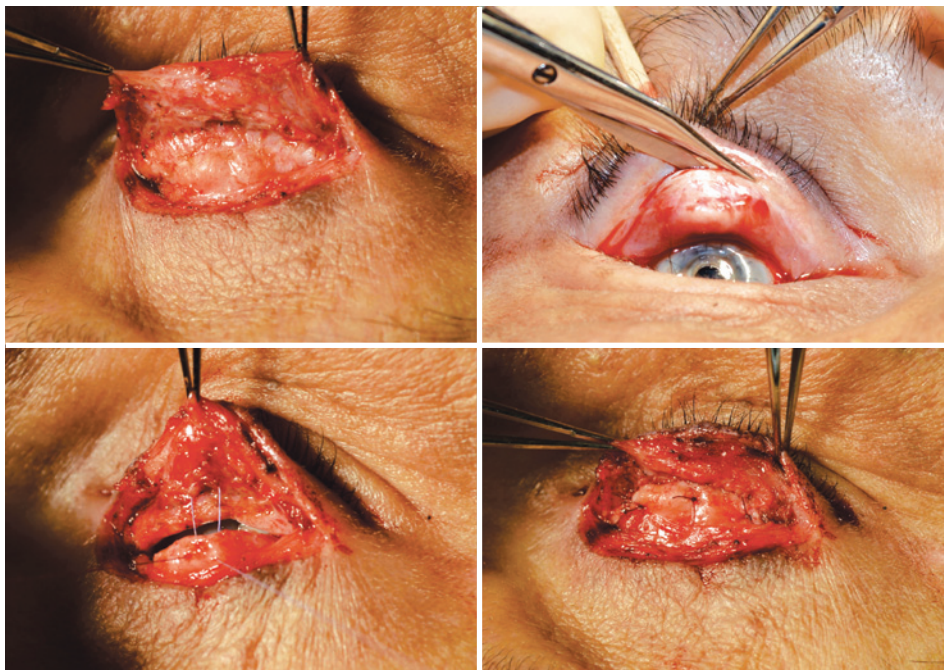
The surgery (Figure 1) is performed with local anesthetic (2% lidocaine with 1:100,000 epinephrine). Initially, a 4-0 silk traction suture is

inserted through the tarsal edge of the lid margin. Next, a standard lid crease incision is used to create a pretarsal skin-muscle flap. At this point, if desired, a standard blepharoplasty skin/muscle resection can be performed. The pretarsal skin-muscle flap is raised, exposing the whole tarsal plate and dissection under the pretarsal orbicularis muscle with Westcott scissors or a Colorado needle proceeds towards the lid margin until the lash roots are visible. The eyelid is everted over a cotton-tipped applicator and held in position with the traction suture. During this maneuver, care is taken to place the applicator under and not over the skin-muscle flap. Using a No. 15 Bard-Parker scalpel blade and Westcott scissors, a curved incision paralleling the lid margin is made through the full thickness of the tarsus 3 mm posteriorly to the margin. Next, the lid is returned to its natural position. Three double-armed 6-0 polyglactin sutures are then passed through the central, medial, and lateral aspects of the distal cut edge of the tarsus and attached to the orbicularis muscle near the lash line. As the sutures are tied, the distal portion of the tarsus is advanced over the marginal tarsus, and the marginal orbicularis is pushed backward, rotating both lamellae of the lid margin outward (Figure 2).

Using this method, the sutures remain within the lid, and no bolsters are used. The lid crease incision is closed with a running 6.0 fast absorbable suture.

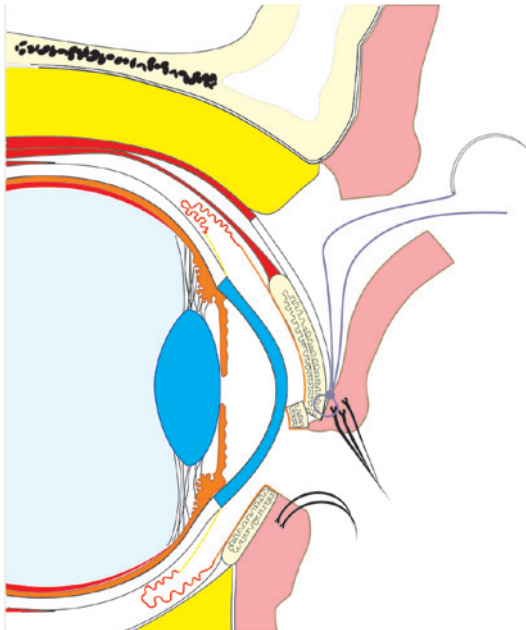
## RESULTS

Sixty upper lids of 40 patients (23 women and 17 men) were operated on, with an age range of 44-99 years [mean  $\pm$  standard deviation (SD) = 70.9  $\pm$  13.01 years]. Bilateral surgery was performed on 21 patients. Follow-up ranged from 1 to 12 months (mean 3.0  $\pm$  2.71 months). Forty percent of the patients (24 lids) had more than 3 months of follow-up, and in this subgroup, the mean postoperative time to final follow-up was 5.6  $\pm$  2.68 months. Trichiasis was corrected in all but one lid, which had two inward lashes medially touching the cornea

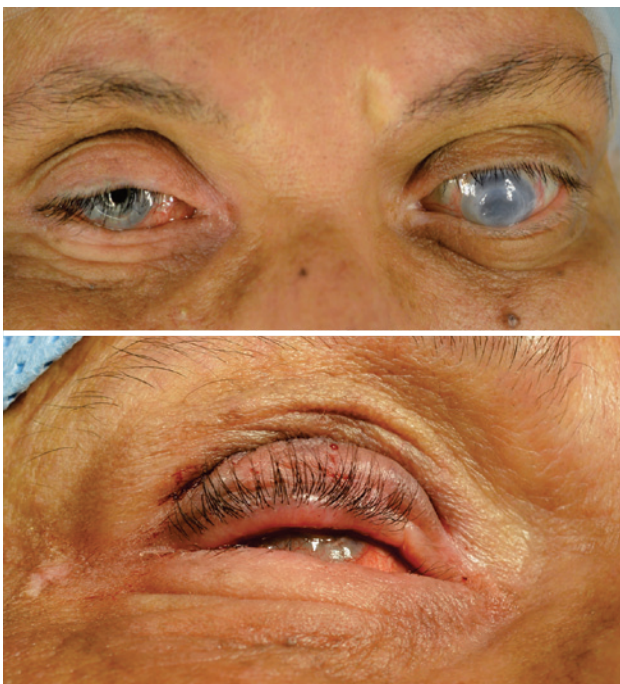

**Figure 1.** Top: Left - a standard lid crease incision is used to raise a pretarsal skin-muscle flap, exposing the whole tarsal flap until the lash roots are visible. Right - tarsotomy is performed with a conjunctival incision 3-4 mm from the lid margin. Bottom: left - a 6-0 Vicryl suture is passed on the orbicularis muscle close to the lash roots and through the mid portion of the distal tarsal fragment. Right - as the sutures are tied, the distal tarsal fragment is slightly advanced over the marginal tarsus and traction is exerted on the orbicularis.

despite adequate margin position, and was managed with lash electrolysis. Figure 3 shows a typical effect of the surgery on patients with cicatricial entropion and residual vision in the right eye.



**Figure 2.** Double mechanism of lid rotation. The distal fragment exerts a downward vector on the marginal tarsus, and the internal suture tractions the anterior lamella near the lash line.



**Figure 3.** Top - a patient with bilateral recurrent cicatricial entropion following surgery performed elsewhere. The left eye is blind and the right has a keratoprosthesis. Bottom-Immediate postoperative result of the lid margin rotation.

## DISCUSSION

UCE is usually seen in aged patients, who may also present with other lid problems, such as dermatochalasis, aponeurotic ptosis, upper sulcus deformity, anterior lamella laxity, and lid retraction. In endemic trichomatous areas, the clinical picture can be quite obvious, with severe trichiasis and blepharospasm. In mild cases, the condition may be difficult to diagnose and is commonly called "rubbing lashes"<sup>(2)</sup>. A typical sign is an abnormal location of the mucocutaneous junction that overlies the meibomian gland line<sup>(13-15)</sup>.

The current literature on the surgical correction of UCE is heavily based on epidemiological studies reporting the outcomes of a large series of procedures that are usually not performed by ophthalmologists from rural communities with few medical resources<sup>(16-18)</sup>. In this context, the ideal procedure is the simplest operation that can be successfully performed in the least amount of time. In African French-speaking countries, the preferred procedure is Trabut surgery, which is a posterior tarsotomy with external sutures secured by bolsters<sup>(12)</sup>. From a mechanical point of view, in this surgery, lid rotation is achieved by the advancement of the distal tarsal portion over the marginal tarsus. The tarsal overlap creates a downward vector on the posterior edge of the marginal tarsus and rotates the lid margin upward.

The World Health Organization recommends the same anterior approach procedure described by Ballen in 1964<sup>(6,10)</sup>. The mechanics involved in the margin rotation in the Ballen procedure is based on a tarsotomy, without any tarsal overlap, and traction on the anterior lamella with external sutures.

We believe that in more conventional surgical settings, an anterior incision placed 3 mm from the margin is not the best approach to address upper lid entropion. There are several advantages with the use of a lid crease incision. Firstly, the tarsal plate and the anterior lamellae are not incised on the same level. This reduces the chances of ischemia of the narrow marginal lid strip that is created with a classic Ballen surgery. Secondly, the suborbicularis dissection can be easily performed until Riolan's muscle is reached. Absorbable sutures can then be passed internally on the marginal portion of the orbicularis muscle, thus increasing the upward rotation of the lashes without the use of bolsters or subsequent suture removal. The absence of bolsters or external sutures renders a more comfortable postoperative care. Thirdly, the tarsal plate is not incised. The distal portion of the tarsus is slightly advanced over the marginal portion, thereby creating the same mechanical downward tension on the margin as described by Trabut<sup>(12)</sup>.

Theoretically, this effect keeps the lid margin rotated, thus decreasing the chances of entropion recurrence. Although the advancement of the distal tarsus fragment over the marginal portion slightly shortens the posterior lamella, we did not observe any retraction, and if needed, the surgeon can address any positional anomalies of the lid recessing or advancing the levator aponeurosis at the end of the margin rotation.

An important limitation of our study is the short postoperative follow-up time. It is well known that the rate of trichiasis recurrence is quite high when non-oculoplastic surgeons perform community-based lid margin rotations<sup>(15,19)</sup>. For example, trichiasis occurs in 20% to 40% of cases after a bilamellar tarsal rotation procedure (Wies/Ballen operation) or a posterior lamellar tarsal rotation (Trabut surgery)<sup>(15,19)</sup>. The recurrence of trichiasis appears to be multifactorial in nature; however, tarsotomies that are non-parallel to the eyelid margin are associated with poor margin rotation<sup>(20)</sup>. The lid crease approach combines the advantage of complete tarsal exposure with the ability to perform the tarsotomy through the conjunctiva; thus, the surgeon is able to simultaneously visualize both the lid margin and tarsal incision at all times, allowing careful control of the location of the tarsotomy.

A discussion on the long-term effects of our margin rotation procedure is not possible at this time. However, we believe that the procedure is stable and can also be used to correct other forms of cicatricial entropion, such as those induced by tarsal buckling after supramaxi-



mal levator resection. The authors have used the described lid crease approach to correct UCE in patients at the King Khaled Eye Specialist Hospital. The level of satisfaction is quite high, and we did not observe any serious complications, such as lid margin necrosis or deficient fissure closure. In addition to the functional outcomes, the cosmetic aspect of this procedure is superior to that of other techniques.

## REFERENCES

1. Polack S, Brooker S, Kuper H, Mariotti S, Mabey D, Foster A. Mapping the global distribution of trachoma. *Bull World Health Organ.* 2005;83(12):913-9.
2. Kersten RC, Kleiner FP, Kulwin DR. Tarsotomy for the treatment of cicatricial entropion with trichiasis. *Arch Ophthalmol.* 1992;110(5):714-7. Comment in: *Arch Ophthalmol.* 1992;110(12):1685.
3. Al-Rifai KM. Trachoma through history. *Int Ophthalmol.* 1988;12(1):9-14.
4. Wies F. Spastic Entropion. *Trans Am Acad Ophthalmol Otolaryngol.* 1955;59(4):503-6.
5. Wies FA. Surgical treatment of entropion. *J Int Coll Surg.* 1954;21(6):758-60.
6. Ballen PH. A Simple procedure for the relief of trichiasis and entropion of the upper lid. *Arch Ophthalmol.* 1964;72:239-40.
7. Merbs SL, West SK, West ES. Pattern of recurrence of trachomatous trichiasis after surgery surgical technique as an explanation. *Ophthalmology.* 2005;112(4):705-9.
8. Sandford-Smith JH. Surgical correction of trachomatous cicatricial entropion. *Br J Ophthalmol.* 1976;60(4):253-5.
9. Reacher MH, Muñoz B, Alghassany A, Daar, AS, Elbualy M, Taylor HR. Controlled trial of surgery for trachomatous trichiasis of the upper lid. *Arch Ophthalmol.* 1992;110(5):667-74.
10. Reacher M, Foster A, Huber J. Trichiasis surgery for trachoma. The bilamellar tarsal rotation procedure. Geneva: World Health Organization; 2001 (WHO/PBL/93.29)
11. Bleyen I, Dolman PJ. The Wies procedure for management of trichiasis or cicatricial entropion of either upper or lower eyelids. *Br J Ophthalmol.* 2009;93(12):1612-5.
12. Trabut G. Entropion-trichiasis en Afrique du Nord. Son opération par voie conjunctivale. *Arch Ophthalmol.* 1949;9:701-7.
13. Sarkies JW. Early changes in margin of upper eyelid in entropion complicating trachoma. *Br J Ophthalmol.* 1965;49(10):538-41.
14. Lucena A1, Akaishi PM, Rodrigues Mde L, Cruz AA. Upper eyelid entropion and dry eye in cicatricial trachoma without trichiasis. *Arq Bras Oftalmol.* 2012;75(6):420-2.
15. Rajak SN, Habtamu E, Weiss HA, Kello AB, Abera Bm Zerugb Nm Gebre CE, et al. The outcome of trachomatous trichiasis surgery in Ethiopia: Risk factors for recurrence. *PLoS Negl Trop Dis.* 2013;7(8):e2392.
16. Gower EW, West SK, Harding JC, Cassard SD, Munoz BE, Othman MS, et al. Trachomatous trichiasis clamp vs standard bilamellar tarsal rotation instrumentation for trichiasis surgery: results of a randomized clinical trial. *JAMA Ophthalmol.* 2013;131(3):294-301.
17. Kerie A, Bejiga A. Pattern of recurrence of trachomatous trichiasis after surgery in Enemor and Ener district, Central Ethiopia. *Ethiop Med J.* 2010;48(4):301-8.
18. Rajak SN, Habtamu E, Weiss HA, Kello AB, Gebre T, Genet A, Bailey RL, et al. Absorbable versus silk sutures for surgical treatment of trachomatous trichiasis in Ethiopia: a randomised controlled trial. *PLoS Med.* 2011;8(12):e1001137.
19. West ES, Mkocho H, Munoz B, Mabey D, Foster A, Bailey R, et al. Risk Factors for post-surgical trichiasis recurrence in a trachoma-endemic area. *Invest Ophthalmol Vis Sci.* 2005;46(2):447-53.
20. Merbs SL, West SK, West ES. Pattern of recurrence of trachomatous trichiasis after surgery. Surgical technique as an explanation. *Ophthalmology.* 2005;112(4):705-9.

# 41º Congresso da Sociedade Brasileira de Retina e Vítreo

21 a 23 de abril de 2016

Mendes Convention Center

Santos - SP

**Informações:**

Site: [www.retina2016.com.br](http://www.retina2016.com.br)