

## Visual loss following cosmetic facial filler injection

### Perda da visão após injeção de preenchimento facial para fins cosméticos

Samir S. Shoughy<sup>1</sup> 

1. The Eye Center, The Eye Foundation for Research in Ophthalmology, Riyadh, Saudi Arabia

**ABSTRACT** | Facial filler injection for soft-tissue augmentation, wrinkle reduction, and rejuvenation has recently become increasingly popular. This procedure is well accepted and widely performed because of its safety and excellent outcomes. However, complications may occur even in the most skilled hands. A 36-year-old female presented with immediate loss of vision in her right eye following the periocular injection of cosmetic hyaluronic acid facial filler into the glabellar region. The visual loss was accompanied by weakness of her left arm. Blindness may complicate cosmetic facial filler injection. The treating physician should have a firm knowledge of the facial vascular anatomy, and the patient should be aware of the potential blinding complications associated with facial filler injection.

**Keywords:** Dermal fillers; Hyaluronic acid; Injections; Cosmetic technique/adverse effects; Vision, low/etiology; Case reports

**RESUMO** | A injeção de preenchimento facial para o aumento de tecido mole, redução de rugas e rejuvenescimento tornou-se recentemente cada vez mais popular. Este procedimento é bem aceito e amplamente realizado devido à sua segurança e excelentes resultados. Porém, complicações podem ocorrer mesmo nas mãos mais habilidosas. Uma mulher de 36 anos apresentou perda da visão no seu olho direito imediatamente após uma injeção periocular de preenchimento facial à base de ácido hialurônico cosmético na região glabellar. A perda visual foi acompanhada de fraqueza no braço esquerdo. A cegueira pode ser uma complicação da injeção de preenchimento facial para fins cosméticos. O médico deve ter um sólido conhecimento da anatomia vascular da face e o paciente deve estar ciente das possíveis complicações associadas à injeção de preenchimento facial.

**Descritores:** Preenchedores dérmicos; Ácido hialurônico; Injeções; Técnicas cosméticas/efeitos adversos; Baixa visão/etiologia; Relatos de casos

Submitted for publication: October 18, 2018  
Accepted for publication: February 5, 2019

**Funding:** No specific financial support was available for this study.

**Disclosure of potential conflicts of interest:** The authors have any potential conflicts of interest to disclose.

**Corresponding author:** Samir S. Shoughy

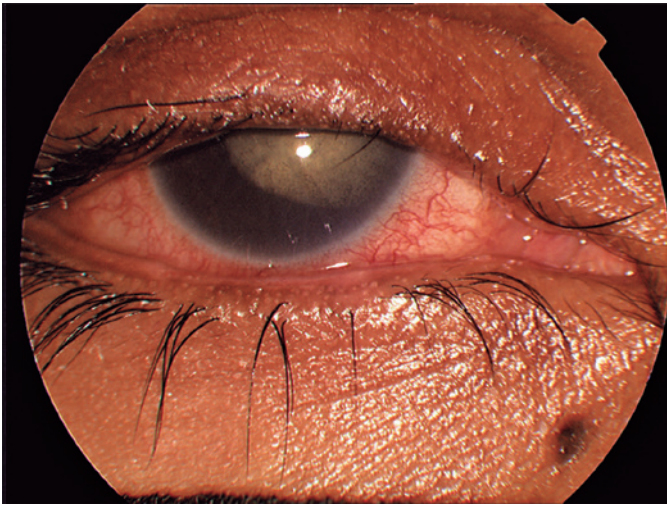
The Eye Center, PO Box 55307, Riyadh 11534, Saudi Arabia  
E-mail: samir.shawki@hotmail.com

## INTRODUCTION

Facial filler injection for soft-tissue augmentation, wrinkle reduction, and rejuvenation has recently become increasingly popular. The procedure is well accepted and widely performed because of its safety and excellent outcomes. However, complications may occur even in the most skilled hands. Adverse events may be devastating and include iatrogenic blindness and stroke<sup>(1)</sup>. Visual loss following filler injection is gaining significant attention because of the increasing number of reports of cosmetic facial filler injection-related retinal artery occlusion<sup>(2)</sup>. We report a case of blindness caused by cosmetic filler injection of hyaluronic acid into the forehead. A retrospective chart review was performed.

## CASE REPORT

A 36-year-old female complained of sudden visual loss in her right eye following hyaluronic acid facial filler injection. The patient brought with her the product injected around her eyes to show us that it was hyaluronic acid. The filler was injected into the glabellar region. The visual loss was accompanied by weakness of the left arm. A review of her systems revealed no history of previous ocular or systemic disease and no known allergies to medications or other substances. She was admitted elsewhere for 20 days and was given oral steroids and aspirin. At presentation, her best corrected visual acuity was no perception of light in the right eye and 20/20 in the left eye. A slit-lamp examination of the right eye revealed swollen lids with multiple areas of dark pigmented lesions and madarosis. The conjunctiva was injected, and stromal edema was evident in the cornea. The pupil was irregular, dilated, and non-reactive. Cataract was evident in the lens (Figure 1). There was no view of the fundus. A diagnostic B-scan revealed choroidal thickening, exudative retinal detachment, and vitreous membranes. The left eye was normal.



**Figure 1.** Photo of the right eye showing swollen lids, madarosis, skin necrosis, conjunctival injection, and cataract.

## DISCUSSION

Facial filler injection is a commonly performed procedure for soft-tissue augmentation and rejuvenation. The procedure is gaining popularity among doctors and patients because of its relative convenience, safety, and pleasing outcomes. However, despite the apparent advantages and simplicity of the procedure, serious side effects may occur, including blindness and stroke. Because of the complexity of the vascular anatomy of the face, ocular complications may occur after injection in any location of the facial region. However, ocular complications occur most frequently following injection into the glabellar region, nasal region, nasolabial fold, and forehead<sup>(3)</sup>.

Patients usually complain of sudden unilateral vision loss, ocular pain, and headache, which occur immediately following injection. In some cases, loss of vision may be accompanied by ophthalmoplegia and ptosis. Our patient developed immediate loss of vision following cosmetic filler injection into the glabellar region without accompanying ophthalmoplegia or ptosis. She developed multiple areas of dark pigmented lesions over the eyelid skin. Skin necrosis associated with facial filler injection was found to be more common in hyaluronic-acid-injected cases compared with injections of autologous fat<sup>(4)</sup>. However, autologous fat was more frequently associated with visual impairment<sup>(5)</sup>.

The proposed underlying mechanism assumes the use of retrograde arterial embolic mechanisms following intravascular injection. The injected tiny droplet may overcome the systolic arterial pressure and move against

the direction of blood flow along the ophthalmic artery. Following release of the injection force, the filler may travel distally into the ophthalmic artery and its branches<sup>(5)</sup>. Injection into the glabellar region may accidentally affect the supraorbital artery or the supratrochlear artery. Kim et al. reported that hyaluronic-acid-injected patients showed occlusion of the distal branches of the ophthalmic artery on selective ophthalmic artery angiograms<sup>(2)</sup>.

In certain circumstances, the injecting force may be high enough that the filler particles may be pushed further retrograde toward the brain circulation. The middle cerebral artery may then be occluded when the force recedes, with subsequent cerebral infarction<sup>(5)</sup>. In our patient, the sudden visual loss in the right eye was accompanied by weakness of the contralateral left arm. This finding highlights the possibility that the injection force was high and might have led to cerebrovascular embolism. Central nervous system complications occur in 23.5% of cases following cosmetic facial filler injection<sup>(6)</sup>. Unfortunately, there are no proven treatments to effectively reverse blindness<sup>(6)</sup>. Several previous measures have been attempted to restore the ophthalmic artery flow. However, none of them were proven effective.

Currently, the treatment of vascular occlusion secondary to facial filler injection is essentially the same as that for non-filler-associated central retinal artery occlusion (CRAOs): it includes lowering the intraocular pressure, anterior chamber paracentesis, and ocular massage. The potential success of these measures is highly linked to early diagnosis and treatment of these cases. The prognosis for vision restoration is poor even with early recognition and treatment<sup>(7)</sup>.

Hyaluronidase injection is currently a proposed treatment modality. Few studies have evaluated orbital, retrobulbar, and intravitreal hyaluronidase<sup>(7)</sup>. Hwang et al. evaluated the efficacy of retrobulbar hyaluronidase injection in rabbits 30 min after occlusion. They found that hyaluronidase failed to reverse the vascular obstruction or restore function following hyaluronic acid gel occlusion of the ophthalmic artery<sup>(8)</sup>. Conversely, DeLorenzi found high dose pulsed hyaluronidase to be very successful in the management of acute filler-related vascular events. The protocol involved solely the administration of repeated high doses of hyaluronidase<sup>(9)</sup>. There are several issues that must be addressed in future studies concerning hyaluronidase use. These include the proper time to initiate therapy, the injection site, and the optimal dose<sup>(10)</sup>.

Hyaluronic acid dermal fillers have been approved by the Food and Drug Administration for use in nasolabial

fills. However, hyaluronic acid is used off-label to restore volume in other areas, including the cheeks and forehead. The treating physician should discuss the “off-label” use of the product in areas other than the nasolabial folds, and this should be stated clearly in the consent form. To minimize the risk of vascular occlusion, the following recommendations should be taken into account: use low injection pressure, inject small volume, and be prepared to deal with a possible acute vascular occlusion<sup>(7,9)</sup>.

In conclusion, despite the apparent safety and rarity of iatrogenic ophthalmic artery occlusion following facial filler injection surgery, blindness remains a possible devastating complication. The treating physicians must have a firm knowledge of the facial vascular anatomy to minimize the incidence of blindness following injection.

## REFERENCES

1. Li X, Du L, Lu JJ. A novel hypothesis of visual loss secondary to cosmetic facial filler injection. *Ann Plast Surg.* 2015;75(3):258-60.
2. Kim YK, Jung C, Woo SJ, Park KH. Cerebral angiographic findings of cosmetic facial filler-related ophthalmic and retinal artery occlusion. *J Korean Med Sci.* 2015;30(12):1847-55.
3. Szantyr A, Orski M, Marchewka I, Szuta M, Orska M, Zapala J. Ocular complications following autologous fat injections into facial area: case report of a recovery from visual loss after ophthalmic artery occlusion and a review of the literature. *Aesthetic Plast Surg.* 2017; 41(3):580-4.
4. Park KH, Kim YK, Woo SJ, Kang SW, Lee WK, Choi KS, Kwak HW, Yoon IH, Huh K, Kim JW; Korean Retina Society. Iatrogenic occlusion of the ophthalmic artery after cosmetic facial filler injections: a national survey by the Korean Retina Society. *JAMA Ophthalmol.* 2014;132(6):714-23.
5. Wu S, Pan L, Wu H, Shi H, Zhao Y, Ji Y, et al. Anatomic study of ophthalmic artery embolism following cosmetic injection. *J Craniofac Surg.* 2017;28(6):1578-81.
6. Myung Y, Yim S, Jeong JH, Kim BK, Heo CY, et al. The classification and prognosis of periocular complications related to blindness following cosmetic filler injection. *Plast Reconstr Surg.* 2017; 140(1):61-4.
7. Hwang CJ. Periorbital injectables: understanding and avoiding complications. *J Cutan Aesthet Surg.* 2016;9(2):73-9.
8. Hwang CJ, Mustak H, Gupta AA, Ramos RM, Goldberg RA, Duckwiler GR. Role of retrobulbar hyaluronidase in filler associated blindness: evaluation of fundus perfusion and electroretinogram readings in an animal model. *Ophthalmic Plast Reconstr Surg.* 2019;35(1):33-7.
9. DeLorenzi C. New high dose pulsed hyaluronidase protocol for hyaluronic acid filler vascular adverse events. *Aesthet Surg J.* 2017; 37(7):814-25. Comment in: *Aesthet Surg J.* 2017;37(7):826-7.
10. DeLorenzi C1. Commentary on: Efficacy of retrobulbar hyaluronidase injection for vision loss resulting from hyaluronic acid filler embolization. *Aesthet Surg J.* 2017;38(1):23-7. Comment on: *Aesthet Surg.* 2017;38(1):12-22.