

Systemic B-cell lymphoma with ocular manifestation and extraocular extension

Linfoma sistêmico de células B com manifestação ocular e extensão extraocular

Sergio Vanetti Burnier ⁽¹⁾
Miguel N. Burnier, Jr. ⁽²⁾

SUMMARY

The authors describe a case of systemic lymphoma with ocular involvement as a histopathologic finding after the enucleation of a blind painful eye. The patient had chronic renal insufficiency and hypertension and had undergone multiple ophthalmologic surgical procedures.

This paper discusses the histopathological aspects of the tumor, moreover the more frequent types of ocular lymphomas.

Key words: Ocular lymphoma; Enucleation; B-cells lymphoma

INTRODUCTION

The ocular presentation of lymphomas is rare, and can be divided basically in its primary form, where it attacks first the retina and vitreous and shows signs and symptoms of an ocular uni or bilateral inflammation, and the secondary or systemic form, where it manifest itself as an uveal tumor, frequently with an extraocular extension. It can be the systemic lymphoma's first manifestation. We can also differentiate this lymphomas according to its cellular origin in T or B cells, with great precision by the immunohistochemistry.

CASE REPORT

Clinical History

A 54-year-old caucasian man had been blind of his left eye since 1980. His past medical history included hypertension and several ophthalmic procedures on his left eye: cataract surgery in 1971, and treatment of a retinal detachment in 1978. In 1980,

this eye was diagnosed as blind and atrophic. In July 1989, because a long-standing renal insufficiency, a successful kidney transplant was performed. In 1992, the patient complained of pain in his blind eye, and an enucleation was performed.

Gross Pathology

The enucleated left eye measured, without including the extraocular mass, 25 x 24 x 24 mm with 3 mm attached optic nerve. The globe did not transilluminate. The cloudy cornea measured 10 x 9 mm. When the eye was opened in the horizontal plane, the anterior chamber was found to be disorganized. The lens was absent. The uveal tract was thickened diffusely and infiltrated by a whitish, firm and homogeneous mass that also involved the episclera, particularly in the posterior part of the eye (Fig. 1). An episcleral nodular mass, measuring 4 x 3 x 3 mm, was located approximately 3 mm temporally from the optic disc nerve head. There was no rupture of the sclera. The tissue comprising the episcleral nodule was identical to that infiltrating the uveal tract (Fig. 2).

McGill University School of Medicine - Department of Ophthalmology, 687 - Pine Avenue West, Room H7-53 - Montreal, Quebec, Canada, H3A - 1A1

⁽¹⁾ Fellow in Oculoplastic at UNIFESP - São Paulo - Brazil

⁽²⁾ Chairman, Department of Ophthalmology, McGill University School of Medicine, Montreal, Quebec, Canada

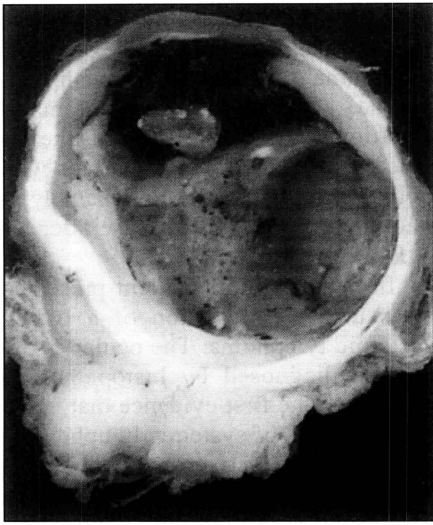


Fig. 1 - Gross photograph of the enucleated left eye shows total retinal detachment and diffuse involvement of the uveal tract by a whitish neoplastic tissue. There is also extraocular nodules of tumor invading the orbital tissues.

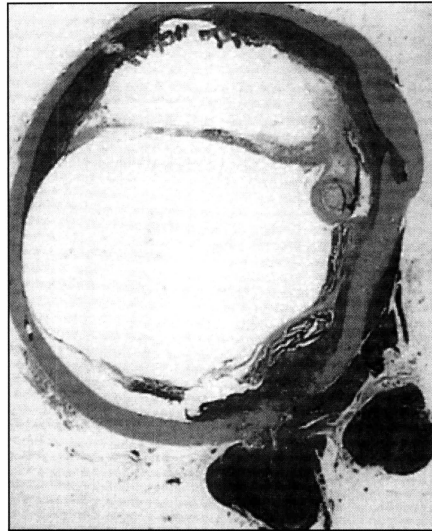


Fig. 2 - Corresponding histopathologic section shows a neoplastic section showing a neoplastic lymphoid proliferation involving the uveal tract as well as the orbital tissue (H&E, whole mount)

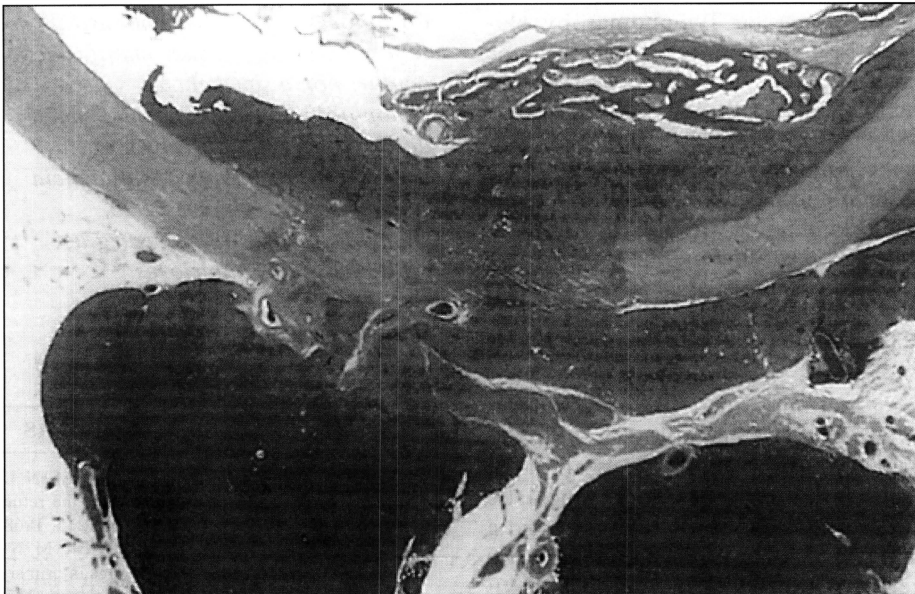


Fig. 3 - Histopathology of the neoplastic cells in both the choroid and orbital tissue (H&E, 100X)

Microscopic Pathology

Histologic sections of the left eye revealed a tumor composed of small, well-differentiated lymphocytes diffusely infiltrating the uveal tract and episclera in a nodular pattern (Fig. 3). The lymphocytes showed mild atypia; nucleoli were visible. Immunohistochemical stains indicated that the vast

majority of the neoplastic cells (80% to 90%) were B-type cells displaying a monoclonal pattern of proliferation (Kappa positive), a finding that supported the diagnosis of B-cell lymphoma (Fig. 4). Intraocular calcification, cholesterol granulomas, and a total retinal detachment were also observed. Immunostains for T cells (UCHL-1)

showed that only 10% were T lymphocytes, all of them being reactive, non neoplastic in nature.

Diagnosis

The diagnosis was well differentiated lymphocytic lymphoma of uveal tract, with extraocular extension.

DISCUSSION

Lymphoma involving the eye is a rare condition which, when it occurs, poses a diagnostic challenge. Confusion exists in the ophthalmic literature regarding the terminology, classification, and clinicopathologic features of this condition. Vogel et al.¹ first noted that ocular lymphomas occur in both a primary and secondary form.

Primary Ocular Lymphoma

Primary ocular lymphoma involves the retina and vitreous. The patient may present with clinical signs and symptoms of ocular inflammation; frequently the initial diagnosis is bilateral uveitis of unknown etiology. The disease is often associated with central nervous system (CNS) lymphoma. The immunohistochemical finding in both the ocular and CNS tumors is that of large B-cell lymphoma.

This group of tumors is widely referred to as reticulum cell sarcomas, a holdover from an earlier lymphoma nomenclature. They represent approximately 1% of non-Hodgkin's lymphomas found at all anatomical sites. Typically occurring in an elderly population (median 60 years), primary intraocular lymphoma first appears as blurred vision and bilateral asymmetric posterior uveitis in patients who have no past history of systemic lymphoma^{1,2}.

Histopathologically, primary intraocular lymphoma usually infiltrate the retina in a multicentric fashion and invade the vitreous with neoplastic and reactive cells. There is a striking tendency for the neoplastic cells to invade the subretinal space, forming masses against the Bruch's membrane that

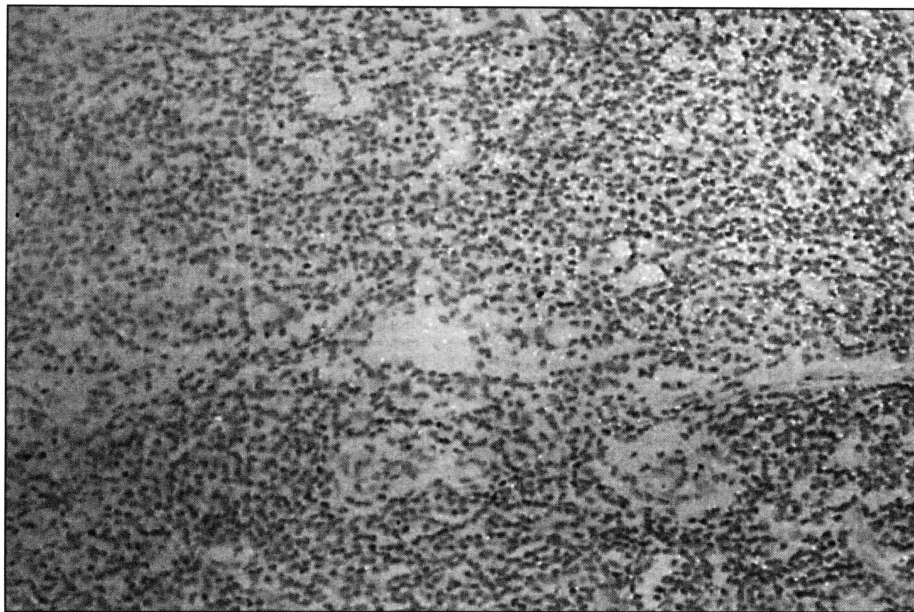


Fig. 4 - Immunohistochemistry showing positive L-26 cells, confirming the diagnosis of B-cell lymphoma

detach the retinal pigment epithelium (RPE).

In the brain, the neoplasm shows the same cytopathologic and immunohistochemical features as it does in the retina. In both the retina and CNS, the neoplastic cells form cuffs or sleeves around blood vessels³. In immunocompetent patients, the uveal tract and orbit are rarely involved and systemic disease seldomly is observed.

Systemic Malignant Lymphoma

In sharp contrast to primary ocular lymphoma, ocular involvement by a systemic malignant lymphoma manifests itself mainly as an uveal tumor, quite often with extraocular extension. Most of these tumors are moderately or well differentiated B-cell lymphomas.

Our patient should be included in this category because the tumor is affecting the choroid with extraocular extension, the retina and the vitreous are not involved and the lymphoma is a well differentiated B cell, with no large cells or areas of necrosis.

Clinically the patient presents with signs and symptoms of an ocular tumor, glaucoma, and proptosis. George et al.⁴ compared the clinical and histopathological features of these two

forms of ocular lymphomas by studying 12 cases of ocular lymphoma from the files of the Armed Forces Institute of Pathology (AFIP). The authors concluded that primary ocular lymphomas occur predominantly in women and usually are bilateral. Ocular inflammatory disease, particularly bilateral posterior uveitis with severe vitritis, was the typical initial clinical presentation. Typically, all the primary cases were diffuse large B-cell lymphomas involving the retina, having neither uveal nor extraocular extension. Histopathologically, these primary lymphomas displayed large areas of necrosis, sleeves of neoplastic cells surrounding blood vessels, and a marked tendency for the neoplastic cells to proliferate between the RPE and Bruch's membrane^{2,4}.

Secondary ocular lymphomas occurred predominantly in men and were usually unilateral. A choroidal mass and proptosis were the most common presenting manifestations. Histopathologically, secondary cases involved the uvea with various proliferative cell types, little or no necrosis, and extraocular extension^{3,4}.

Secondary lymphomas were often associated with systemic disease. In

some instances the eye was the site of the first manifestation of the systemic lymphoma (extranodal malignant lymphoma) and the other systemic manifestations occurred later on in the disease. About 25% of the patients with both forms of ocular malignant lymphoma developed the disease after organ transplantation.

In summary, our patient presented an ocular manifestation of a B cell systemic lymphoma. The ocular disease was diagnosed by histopathology and it was the first evidence that led to the diagnosis of systemic lymphoma.

This case also brings the importance of a careful ocular examination of a blind painful eye including ultrasonography to diagnose any occult associated conditions.

RESUMO

Os autores descrevem um caso de linfoma sistêmico, com manifestação ocular, como um achado histopatológico após a enucleação de um olho cego doloroso. O paciente apresentava insuficiência renal crônica e hipertensão, submetido a múltiplas cirurgias oftalmológicas anteriores.

Palavras-chave: Linfoma ocular; Enucleação; Linfoma de células B

REFERÊNCIAS BIBLIOGRÁFICAS

1. VOGEL, M. H.; FONT, R. L.; ZIMMERMAN, L. E.; et al. - Reticulum cell sarcoma of the retina and uvea. *Am J Ophthalmol*, **66**: 205-215, 1968.
2. LOPEZ, J. S.; CHAN, C. C.; BURNIER, M. N., et al. - Immunohistochemistry findings in primary intraocular lymphoma. *Am J Ophthalmol*, **112**: 472-474, 1991.
3. BURNIER, M. N.; FENTON, R. M. - Large B-cell lymphoma of the retina and CNS. Case presentation. Meeting of the Pan American Association of Ophthalmic Pathology, Anaheim, California, 1991.
4. GEORGE, D. P.; McLEAN, I. W.; BURNIER, M. N.; et al. - Clinicopathological differentiation of primary and secondary ocular lymphomas. *IVOS*, **34**: 970, 1993.
5. McLEAN, I. W.; BURNIER, M. N.; ZIMMERMAN, L. E.; JACKOBIEK, F. A. - Tumor of the eye and ocular adnexa. Fascicle 12. The Armed Forces Institute of Pathology, Washington DC, 1995.