

---

# Retinal toxicity of ceftazidime in the infusion fluid for vitrectomy in the rabbit eye

*Toxicidade da ceftazidima no líquido de perfusão para vitrectomia em olho de coelho*

Ismael Ribeiro  
Chanping Liang  
Gholam A. Peyman

## SUMMARY

**Background and Objective:** We investigated the retinal toxicity of ceftazidime, a third-generation cephalosporin, in the infusion fluid during vitrectomy.

**Study Design/Materials and Methods:** Twenty-two New Zealand rabbits underwent examination, electroretinogram, and complete vitrectomy. Infusion solutions with ceftazidime were used in the right eyes at the following concentrations: 20 (n = 2), 40 (n = 4), 80 (n = 5), 100 (n = 2), 150 (n = 2), 200 (n = 2) and 300 µg/mL (n = 5). Left eyes were infused with balanced salt solution. Animals were examined daily for 2 weeks, underwent electroretinograms 2 weeks postoperatively and, then, were sacrificed for light and electron microscopy.

**Results:** Electroretinogram findings were normal at concentrations of 20, 40, 100 and 150 µg/mL. In the 80 µg/mL group, 1 of 5 animals had significant changes. In the 200 and 300 µg/mL groups, significant decreased in amplitude were noted. Retinas exposed to 300 µg/mL demonstrated minimal changes in the rod outer segments of the photoreceptor layer.

**Conclusion:** We found concentrations up to 150 µg/mL ceftazidime in the infusion fluid to be nontoxic to the retina.

**Keywords:** Vitrectomy; Ceftazidime; Infusion fluid; Retinal toxicity; Endophthalmitis.

---

## INTRODUCTION

Bacterial endophthalmitis is the most dreaded complication in the period after intraocular surgery and after penetrating injuries of the globe<sup>1-4</sup>. The disease also may be associated with a systemic infection. As an infectious process of the internal structures of the eye, it commonly leads to a significant decrease in visual acuity and even to loss of the eye<sup>4,5</sup>. The prognosis is particularly poor for infections caused by gram-negative pathogens<sup>6</sup>.

Because topical, subconjunctival, and systemic antibiotics are often ineffective in treating endophthalmitis<sup>4</sup>, intravitreal injection of antibiotics with or without vitrectomy can favorably alter the outcome of the disease<sup>7,8</sup>. The use of antimicrobial drugs in the infusion fluid during vitreous surgery in the treatment or prevention of endophthalmitis has been advocated<sup>3,9</sup>. Before any procedure, vitreous and aqueous taps should be performed to provide samples for culture and antibiotic sensitivity. Because any delay in initiating appropriate therapy can worsen the prognosis, the practice is to

---

From the LSU Eye Center, Louisiana State University Medical Center School of Medicine, New Orleans, LA.

Supported in part by U.S. Public Health Service grants EY07541 and EY02377 from the National Eye Institute, National Institutes of Health, Bethesda, MD and by an unrestricted departmental grant from Research to Prevent Blindness, New York, NY.

Address reprint requests to: Dr. Ismael Caixeta Ribeiro. Hospital Santa Lúcia - Av. Santos Dumont, 334. Centro, Uberaba (MG) CEP 38010-370.

initially treat with broad-spectrum antibiotics. The most common regimens are associated with antimicrobials that have good activity against gram-positive and gram-negative bacteria. The aminoglycosides have very good action against gram-negative organisms and are commonly employed, but severe retinal toxic reactions have been reported<sup>1</sup>. For this reason, we are evaluating the toxicity of ceftazidime diluted in the infusion solution. Ceftazidime is a third-generation cephalosporin with potent bactericidal activity against gram-negative rods which showed no toxic effects when injected intravitreally in the concentration of 2.25 mg in 0.1 mL of balanced salt solution<sup>1</sup>.

---

## MATERIALS AND METHODS

---

### *Antibacterial Agent*

Ceftazidime was obtained as a powder from Eli Lilly & Co. (Indianapolis, Ind.) and was diluted in 500 mL of sterile balanced salt solution (BSS) to concentrations of 20, 40, 80, 100, 150, 200 and 300 µg/mL. The solution was made fresh on the day of use.

### *Animals*

Twenty-two right eyes of 22 New Zealand white rabbits weighing 2-3 kg were used in the experiment; the left eyes (n = 22) were used as controls. The rabbits were cared for according to the Association for Research in Vision and Ophthalmology resolution on the use of animals in research. Indirect ophthalmoscopic examination was performed on all rabbits after dilation of pupils with tropicamide 1% (Mydracyl 1%, Alcon Laboratories, Inc, Fort Worth, TX), and phenylephrine hydrochloride (Mydrin 2.5%, Alcon) and all eyes were found to be normal.

### *Electroretinography*

For electroretinography (ERG), the rabbits were dark-adapted for 30 min and then anesthetized with a mixture of ketamine (50 mg/kg) and xylazine (5 mg/kg). Pupils were dilated and ERGs were recorded using gold contact lenses and stainless steel needle electrodes positioned behind the ears (reference) and on the forehead (ground). Scotopic conditions involved a 10 µsec Ganzfeld flash (1 per 10 sec) of blue light (Wratten filter N° 47) at low intensity (events 1 and 2). The low-intensity exposure was repeated without the blue filter (events 3 and 4). The light intensity was increased to medium in events 5 and 6 and to high for events 7 and 8, using strobe generator Model 1539-A (General Radio, Concord, MA).

Vitrectomy infusion solutions were prepared using ceftazidime in BSS in the concentrations mentioned above. Concentrations of 20 µg/mL were used in 2 eyes, 40 µg/mL in 4 eyes, 80 µg/mL in 5 eyes, 100 µg/mL in 2 eyes, 150 µg/mL in 2

eyes, 200 µg/mL in 2 eyes and 300 µg/mL in 5 eyes. All left eyes served as controls, receiving only BSS as infusion fluid. We used more eyes in the concentrations of 40 µg/mL and 80 µg/mL because we thought that could be the ideal concentrations to use, and 300 µg/mL to better evaluate any signs of toxicity that could appear with this concentration.

Complete vitrectomy was performed via the pars plana. A 360° peritomy and three sclerotomies were made with a microvitrectomy (MVR) blade, 4 mm posterior to the limbus. The infusion cannula was located superiorly and the other two sclerotomies located inferiorly were used for the insertion of the fiberoptic light pipe and the vitrectomy probe. The procedures lasted 15-20 min and a minimum of 120 mL of infusion solution containing the drug was used during each operation. The infusion cannula was fixed with 5-0 Dacron sutures and the sclerotomies were closed with 6-0 polyglactin after the instruments were withdrawn. The conjunctiva was also repaired with 6-0 polyglactin sutures.

The rabbits were examined daily for two weeks after surgery by means of external examination and indirect ophthalmoscopy. Two weeks after surgery, ERGs were performed in the same manner and the rabbits were sacrificed by intravenous injection of 1 mL sodium pentobarbital. The eyes were enucleated and processed either for light or electron microscopy.

---

## RESULT

---

All animals showed mild to moderate eyelid and conjunctival edema. Three presented with discrete posterior cataracts caused by surgical trauma (80 µg/mL and 300 µg/mL); two presented with small and localized vitreous hemorrhage at the time of sclerotomy closure in the inferior quadrant (80 µg/mL). None of the complications impaired visualization of the retina, which appeared normal by indirect ophthalmoscopy at all concentrations used. Vitreous hemorrhage had almost cleared by the second week.

Preoperative and postoperative ERGs were compared for all animals. Because of normal variation in amplitude in rabbit ERGs, variations of less than 25% of the preoperative ERG were considered insignificant. Variations of 25% to 50% were rated significant and more than 50% reduction in amplitude was rated severe. No significant changes in the ERG were found in eyes given infusion fluid containing concentrations of 20 µg/mL and 40 µg/mL. With the use of 80 µg/mL, 1 of 5 eyes developed changes classified as significant (35% of the preoperative ERG). In the concentration of 100 and 150 µg/mL, there were no significant alterations in the ERG, but with 200 and 300 µg/mL, the postoperative ERG had a significant decrease in amplitude, especially in the first two events (scotopic). In the control group, the alterations of ERG were considered insignificant.

### *Light Microscopy*

None of the treated eyes showed significant alterations in

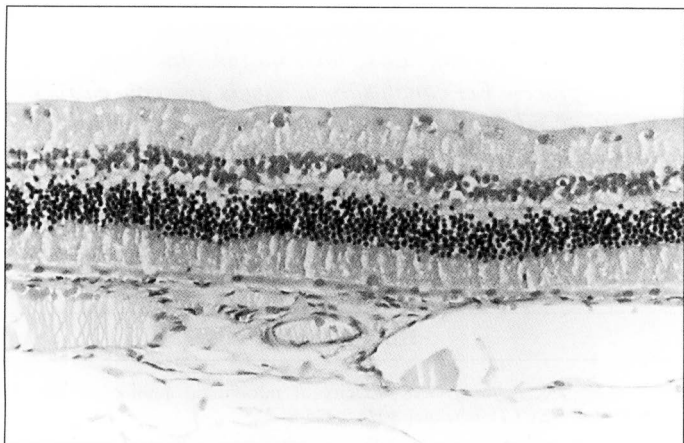


Fig. 1 - Light micrograph of the retina from an eye which received 300 µg/mL ceftazidime infusion fluid, demonstrating mild irregularity of the outer segments of the photoreceptors. (Hematoxylin and eosin, X 200).

morphology of the normal retinal structures when observed by light microscopy (Figure 1). The retinas that were exposed to 300 µg/mL in the replacement fluid demonstrated only minimal changes in the rod outer segments of the photoreceptor layer (Figure 2).

#### Electron Microscopy

Electron microscopic examination revealed no differences in the appearance of the retina and retinal pigment epithelium between the control rabbit eyes and the eyes that received 20

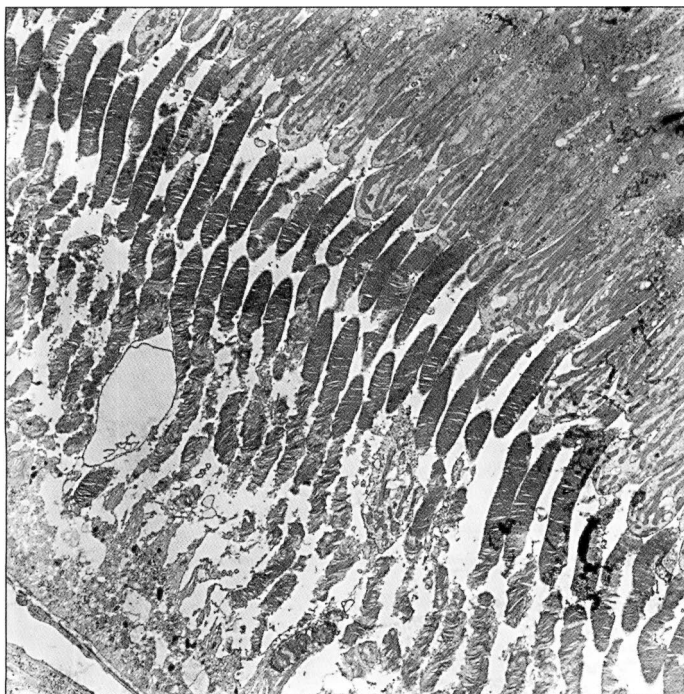


Fig. 2 - Electron micrograph of an eye which received 300 µg/mL ceftazidime infusion fluid, demonstrating disorganization and breakdown of the disc membrane at the distal part of the outer segment. (Uranyl acetate and lead citrate, X 1600).

Table 1. Retinal Toxicity of Ceftazidime in Infusion Fluid for Vitrectomy.

Concentration of ceftazidime µg/mL of BSS	Dosage and Results		
	Number of eyes	Histology	ERG
0 (control)	22	normal	normal
20	2	normal	normal
40	4	normal	normal
80	5	normal	reduced amplitude (1 of 5)
100	2	normal	normal
150	2	normal	normal
200	2	normal	reduced amplitude
300	5	abnormal changes	reduced amplitude

and 40 µg/mL (Figure 3). No EM pictures were taken in the 100, 150 and 200 µg/mL group. In the group which received 300 µg/mL, the signs of retinal changes, confined to the distal part of the outer segments of the photoreceptors, consisted of disorganization and breakdown of the disc membrane (Figure 4). No significant changes were seen in the inner segments of the photoreceptor and the nuclear layers. Dosage and results (ERG and histology) are summarized in Table 1.

#### DISCUSSION

In the presence of intraocular infection, the use of either intravitreal injection of drugs or vitrectomy with antibiotics in the infusion fluid, along with parenteral therapy is recommended<sup>5</sup>. The most commonly employed antibiotic regimen for intravitreal injection is the combination of vancomycin<sup>12</sup>, which demonstrates good activity against gram-positive organisms, and an aminoglycoside (active against gram-negative organisms)<sup>13,9</sup>; however, retinal toxicity is associated with aminoglycoside use because the minimum inhibitory concentration (MIC) is close to the safe concentration of the drug<sup>1,10,13-15</sup>. A safer drug which provides good protection against gram-negative organisms is needed, as infections caused by these organisms have a poor prognosis<sup>6,11</sup>.

Ceftazidime, a third-generation cephalosporin, has potent bacterial activity against gram-negative rods, especially *Pseudomonas aeruginosa*, and some activity against gram-positive organisms<sup>7,14</sup>. *P. aeruginosa* is one of the leading causes of severe hospital infections<sup>16</sup>. Although this microorganism is intrinsically resistant to many antibiotics, most strains are relatively susceptible to ureide penicillins, some third-generation cephalosporins, imipenem, the newer quinolones, and amikacin. Ceftazidime is one of the most active antibiotics to inhibit *P. aeruginosa*<sup>16,17</sup>.

The minimal inhibitory concentration (MIC<sub>90</sub>) for amino-

glycoside-sensitive *P. aeruginosa* of ceftazidime is 8 mg/l, and the MIC<sub>90</sub> for strains resistant to one or more aminoglycosides is 128 mg/l. The MIC<sub>90</sub> for *Pseudomonas aeruginosa* isolates highly resistant to all three aminoglycosides (MIC<sub>90</sub> > 128 mg/l) is 32 mg/l for ceftazidime.

A 2.25 mg intravitreal dose of ceftazidime has been proven nontoxic to the retina<sup>10</sup>. We tested the toxicity of ceftazidime in the infusion fluid and found that at concentrations of 20, 40, 80, 100 and 150 µg/mL, there were no signs of retinal toxicity, either by ERG or histology. At concentrations of 200 and 300 µg/mL (300 µg/mL is the same as 45 mg into 150 ml of BSS), the ERGs changed significantly and histological examination showed small alterations in the outer segments of the photoreceptors<sup>16</sup>. (Figs. 1 and 2).

We found that 150 µg/mL of ceftazidime is safe for ocular tissue and still effective in the treatment of gram-negative endophthalmitis. We believe that 200 µg/ml is a borderline dosage and further studies should be done, specifically in primates, because in previous studies on ceftazidime toxicity, the macula was shown to be the site of the retina that was most affected by high doses (macular cyst or hole formation).

As ceftazidime has a low level of activity against *Staphylococcus aureus* and *S. epidermidis*, it should always be used in combination with a drug that has good activity against gram-positive bacteria for the treatment or prevention of endophthalmitis.

#### RESUMO

*Investigamos a toxicidade retiniana de ceftazidima, uma cefalosporina de terceira geração, no fluido de infusão durante vitrectomia. Vinte e dois coelhos Nova Zelândia foram examinados, e submetidos a eletrorretinograma e vitrectomia. Soluções de infusão com ceftazidima foram usadas nos olhos direito nas seguintes concentrações: 20 (n = 2), 40 (n = 4), 80 (n = 5), 100 (n = 2), 150 (n = 2), 200 (n = 2) e 300 µg/mL (n = 5). Foi usada nos olhos esquerdos, infusão com solução salina balanceada (BSS). Os animais foram examinados diariamente por 2 semanas, eletrorretinograma feito 2 semanas após a cirurgia, e então, sacrificados para realização de microscopia óptica e eletrônica. Os achados de eletrorretinograma foram normais nas concentrações de 20, 40, 100 e 150 µg/mL. No grupo de 80 µg/mL, 1 de 5 animais teve alterações significativas. Nos grupos de 200 e 300 µg/mL, diminuição significativa de amplitude foi observada. Retinas expostas a*

*300 µg/mL demonstraram somente alterações mínimas nos segmentos externos dos bastonetes da camada de fotorreceptores. Em conclusão, achamos que concentrações até 150 µg/mL de ceftazidima no fluido de infusão não é tóxico à retina.*

**Palavras-chave:** Vitrectomia; Ceftazidima; Fluido de infusão; Toxicidade retiniana; Endoftalmite.

#### REFERENCES

1. Bennett TO, Peyman GA. Toxicity of intravitreal aminoglycosides in primates. *Can J Ophthalmol* 1974;9:475-8.
2. Bohigian GM, Olk RJ. Factors associated with a poor visual result in endophthalmitis. *Am J Ophthalmol* 1986;101:332-4.
3. Forster RJ, Zachary IG, Cottingham AJ Jr, Norton EWD. Further observations on the diagnosis, cause, and treatment of endophthalmitis. *Am J Ophthalmol* 1976;81:52-6.
4. Junior, CAM, Moreira AT, Bonomo PP, Liggett PE, Trousdale MD. Hialuronato de sódio como veículo para gentamicina intraocular: estudo "in vitro". *Rev. Bras. de Oftalmol* 1990;49:13-20.
5. Diamond JG. Intraocular management of endophthalmitis: A systematic approach. *Arch Ophthalmol* 1981;99:96-9.
6. Puliafito CA, Baker AS, Haaf J, Foster CS. Infectious endophthalmitis: Review of 36 cases. *Ophthalmology* 1982;89:921-9.
7. Shockley RK, Fishman P, Aziz M, Yannis RA, Jay WM. Subconjunctival administration of ceftazidime in pigmented rabbit eyes. *Arch Ophthalmol* 1986;104:266-8.
8. Junior CAM, Moreira AT, Bonomo PP, Liggett PE, Trousdale MD. Hialuronato de sódio como veículo para gentamicina intraocular: estudo "in vivo" - parte II. *Rev Bras de Oftalmol* 1990;49:193-9.
9. Molinari LC. Endoftalmite - Aspectos profiláticos e terapêuticos. *Rev Bras Oftalmol* 1995;54:355-61.
10. Campochiaro PA, Green WR. Toxicity of intravitreal ceftazidime in primate retina. *Arch Ophthalmol* 1992;110:1625-9.
11. Lim JI, Campochiaro PA. Successful treatment of gram-negative endophthalmitis with intravitreal ceftazidime (letter). *Arch Ophthalmol* 1992;110:1686.
12. Borhani H, Peyman GA, Wafapoor H. Use of vancomycin in vitrectomy infusion solution and evaluation of retinal toxicity. *Int Ophthalmol* 1993;17:85-8.
13. Pflugfelder SC, Hernandez E, Fliesler SJ, Alvarez J, Pflugfelder ME, Forster RK. Intravitreal vancomycin: Retinal toxicity, clearance, and interaction with gentamicin. *Arch Ophthalmol* 1987;105:831-7.
14. Campochiaro PA, Conway BP. Aminoglycoside toxicity: A survey of retinal specialists. Implications for ocular use. *Arch Ophthalmol* 1991;109:946-50.
15. Conway BP, Campochiaro PA. Macular infarction after endophthalmitis treated with vitrectomy and intravitreal gentamicin. *Arch Ophthalmol* 1986;104:367-71.
16. Takigawa K, Fujita J, Negayama K et al. Comparing antimicrobial activity against resistant *Pseudomonas aeruginosa* using an index for the absence of cross resistance. *J Antimicrob Chemother* 1995;35:435-27.
17. Baltsch AL, Smith RP, Ritz W. Comparative antimicrobial activity of FK037, cefpirome, ceftazidime and Cefepime against aminoglycoside-sensitive and aminoglycoside-resistant *Pseudomonas aeruginosa* and *Pseudomonas spp.* *Chemotherapy* 1994;40:391-8.

## Novidades na Internet!!!

Agora no site CBO você tem disponível todas as informações na íntegra dos Arquivos Brasileiros de Oftalmologia

<http://www.cbo.com.br/abo>