

Jelly petrolatum conjunctival granuloma: a case report

Relato de um caso de granuloma conjuntival induzido por vaselina

Carlos E. Pavésio ^{(1)*}
 Jack Whitcher ⁽¹⁾
 Howard B. Ostler ⁽¹⁾

SUMMARY

The authors report a case of a conjunctival granuloma occurring as a complication of a paranasal sinus procedure. Bilateral fractures of the ethmoid bones allowed the subconjunctival infiltration of the jelly petrolatum commonly used at the end of these procedures.

Key-words: Conjunctival granuloma; Jelly petrolatum.

INTRODUCTION

The use of jelly-petrolatum (vaseline) gauze, and vaseline ointments and antibiotics is common in paranasal sinus procedures. We are unaware of any ocular complications having been reported in association with this technique. Herein we report a case of conjunctival granulomas and extrusion of vaseline under the conjunctiva following such a procedure.

CASE REPORT

A 44 year old caucasian woman, was seen by us with a complaint of bilateral conjunctival blisters and redness of the left eye. Approximately four months previously, she had undergone pansinsectomy for chronic sphenoid and ethmoid sinusitis. During surgery the ethmoid bones, which were described as "paper thin" by the surgeon, were fractured on both sides. At the end of surgery the nasal cavity was firmly packed with vaseline gauze permeated with polysporon ointment. In the first day post-operative the patient had marked bilateral swelling and ecchymosis of her eyelids and a left exotropia. She was treated with prednisone (40mg/day) and Keflex (1.0 gram a

day) and had marked resolution within 8 days. Four weeks after surgery she noticed white blisters on her nasal conjunctiva bilaterally, more prominent in the left eye.

Her best corrected visual acuity was 20/20 in both eyes; the pupils and extra-ocular muscles were within normal limits. Slit lamp examination of the palpebral conjunctiva OU revealed a mild papillary reaction superiorly. The bulbar conjunctiva revealed a firm, gelatinous, sub-conjunctival/inter-conjunctival mass in the medial aspect of the right eye (Fig. 1), surrounded by several, much smaller, oily-looking masses; the nasal bulbar conjunctiva of the left eye revealed a similar but larger mass. The rest of her examination was unremarkable, with intra-ocular pressures of 18 mmHg OU and Hertel measurements of 16 mm OU, with a base of 105 mm. Attempts to remove the material from under the conjunctiva using fine needle puncture was relatively successful cosmetically in the right eye only. The material which was removed was identified as petrolatum. One year after sinus surgery the patient had developed a large inflamed granuloma of the nasal bulbar conjunctiva in the left eye (fig). This large sub-conjunctival mass was surgically removed and during the operation the left

Trabalho realizado na Francis I. Proctor Foundation University of California - San Francisco

⁽¹⁾ Francis I. Proctor Foundation, University of California, San Francisco.

* Departamento de Oftalmologia, Escola Paulista de Medicina, Sao Paulo.

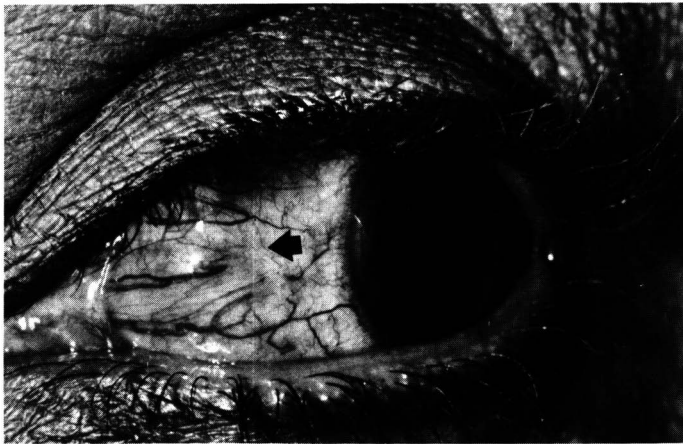

Figura 1

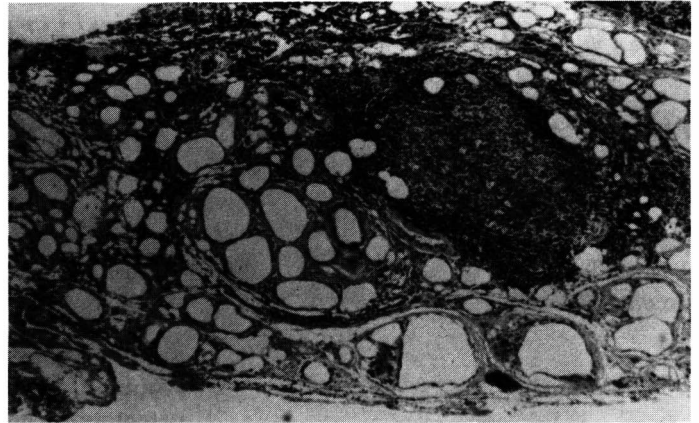


Figura 2

medial rectus muscle was found to be infiltrated. The mass in this area was partially resected, and it was also identified as petrolatum jelly. The microscopic examination revealed numerous cystic spaces lined by relatively flattened cells, associated with an infiltrate of lymphocytes, plasma cells, epithelioid cells, and occasional giant cells; in one area there was a well defined lymphoid follicle with reticulum cells in the center and well differentiated lymphocytes around the edge. (Fig. 2)

DISCUSSION

The use of vaseline gauze and vaseline based ointment is common practice after sinus surgery. Ocular complications have not been reported. However, we are aware of three reports of vaseline-like products in the eyelids. In one case, self-inoculation of vaseline in the lower lids, bilaterally, was performed for cosmetic reasons⁽¹⁾. In two cases infiltration of the lower lid occurred iatrogenically during radio-

graphic exploration of the lacrimal excretory system^(2,3). Previous studies with silicone and petrolatum jelly have not demonstrated acute inflammatory responses^(4,5,6). Normally the material causes a granulomatous foreign body reaction only.

Given the history of fracture of both ethmoid bones and extensive nasal packing with vaseline gauze, the subconjunctival vaseline probably arose from that source. We feel the vaseline probably extruded into the orbit through the fractures of the ethmoid bones and along with blood was extruded between the conjunctiva and Tenon's capsule.

The conjunctiva granuloma was excised mostly for cosmetic reasons. Careful resection was necessary to prevent damage to the extra-ocular muscles.

RESUMO

Os autores relatam um caso de granuloma da conjuntiva que ocorreu em consequência de uma

complicação de uma cirurgia dos seios para-nasais. Fraturas bilaterais dos ossos etmoidais possibilitaram a infiltração subconjuntival da vaselina comumente utilizada ao final dessas cirurgias.

REFERENCES

1. BOYTON, J. R.; SEARL, S. S.; HEIMER, J. L.; MILLER, E. A. - Eyelid oleogranuloma caused by petrolatum jelly injection. *Arch. Ophthalmol.*, 1988 Apr; 106(4):550-1
2. CREHANGE, J. R.; AROUETE, J.; MOULY, R.; RIVIERE, R.; GRUPPER, C. - Palpebral vaselinoma after drug injections in the lacrimal ducts. *Bull. Soc. Ophthalmol. Fr.*, 1970, Dec; 70(12):1202-6.
3. AROUETE, J.; GRUPPER, C.; BELTZER, E. Vaseline of the eyelid (2nd case). *Bull. Soc. Fr. Dermatol. Syphiligr.*, 1970; 77(6):808-10.
4. REES, T. D.; BALLANTYNE, D. L. Jr.; SEIDMAN, I., et al. - An investigation of cutaneous response to dimethylpolysiloxane (silicone liquid) in animals and humans: A preliminary report. *Plast. Reconstr. Surg.*, 1965; 35:131-9.
5. REES, T.; BALLANTYNE, D. L. Jr.; SEIDMAN, I., et al. Visceral response to subcutaneous and intraperitoneal injections of silicone in mice. *Plast. Reconstr. Surg.*, 1967; 39:402-10.
6. BEN-HUR, N.; BALLANTYNE, D. L. Jr.; REES, T. D., et al. Local and systemic effects of dimethylpolysiloxane fluid in mice. *Plast. Reconstr. Surg.*, 1967; 39:423-6.