

# Experimental intraoperative use of perfluorotributylamine, perfluorodecaline, and perfluoropolyether

Utilização intra-operatória experimental de perfluorotributilamino, perfluorodecalino e perfluoropoliéter

Joaquim M de Queiroz, Jr.  
Serdar A. Özler  
Peter E. Liggett  
Carlos A. Moreira, Jr.  
D. Virgil Alfaro

## ABSTRACT

The perfluorocarbon liquids (PFCLs) are a group of compounds with a specific gravity greater than water that are used as an adjunct in the surgical management of complicated vitreoretinal diseases. Thirty-two pigmented rabbits underwent vitrectomy with injection of one of three PFCLs or saline into the vitreous cavity: eight eyes received perfluorotributylamine (PFTA); eight eyes received perfluorodecaline (PFDC); eight eyes received perfluoropolyether (PFPE); the remaining eight eyes, which served as controls, received saline. One hour after placement in the eyes the PFCLs were removed from the vitreous cavity and the eyes were filled with saline. The rabbits were then euthanized and the eyes enucleated and processed for histologic examination. Light microscopy demonstrated no significant difference between eyes with the PFCLs compared with those of control animals. Electron microscopy revealed only minor changes, consisting of a few irregularly shaped defects in the outer segment discs of photoreceptors, in the PFDC group only. These findings suggest that short-term intraoperative use of PFTA, PFPE, and PFDC, at least in this experimental animal model, is not associated with any significant retinal pathology.

**Key words:** Experimental, intraoperative, perfluorocarbon liquids, vitrectomy.

## INTRODUCTION

Vitreoretinal surgeons have long sought a vitreous substitute that is transparent, viscous, and heavier than water, that does not interfere with refraction and, most of all, is not toxic to the retina or other structures of the eye. Currently, silicone oil is most widely used as a vitreous substitute, although there are some problems with its use and controversy over its possible toxicity

continues<sup>(1-8)</sup>. In addition, silicone oil has a low specific gravity, and thus is not of benefit in the repair of inferior breaks or for intraoperative management of complicated retinal detachments<sup>(9,10)</sup>.

Liquid perfluorochemicals meet many of the criteria that are desirable in a vitreous substitute, and several have been tested as potential vitreous substitutes<sup>(11-18)</sup>. Unfortunately, a number of these agents cause ocular toxicity or other problems<sup>(12,15)</sup>.

From the Doheny Eye Institute, and the Department of Ophthalmology, University of Southern California School of Medicine, Los Angeles, California.

Presented in part at the annual meeting of the Association for Research in Vision and Ophthalmology, Sarasota, Florida, April 30, 1991.

Reprint requests: Joaquim M. de Queiroz, Jr., Tv. Mauriti 3157, Bairro Marco, Belém, Pará, Brasil, CEP 66240.

Recently CHANG and coworkers<sup>(19-22)</sup> described the use of perfluorocarbon liquids (PFCLs) for unfolding retinal flaps and in management of proliferative vitreoretinopathy. PFCLs, when used experimentally, tend to cause retinal toxicity at about 30 days following injection,<sup>(12,14,16)</sup> and thus are used only in the intraoperative period, and are removed once the surgical goal of retinal reattachment has been achieved.

The purpose of this study was to evaluate any structural changes in the retina caused by three different PFCLs after one hour in rabbit eyes.

---

#### MATERIALS AND METHODS

---

All experiments adhered to the *Association for Research in Vision and Ophthalmology* Resolution on the Use of Animals in Research. Thirty-two Dutch cross rabbits (2 to 3 kg) were used to evaluate the one-hour ocular tolerance to three different PFCLs injected intraoperatively. Perfluorotributylamine (PFTA), perfluorodecaline (PFDC), and perfluoropolyether (PFPE) were the PFCLs studied. Each of these PFCLs was injected into eight eyes; as controls, eight eyes were similarly injected with saline.

Maximum mydriasis was achieved by topical application of phenylephrine hydrochloride 2.5% and tropicamide 1%. Animals were anesthetized with an intramuscular injection of 0.75 mL/kg ketamine hydrochloride (100 mg/mL) and xylazine hydrochloride (20 mg/mL) in a 1:1 solution. Proparacaine hydrochloride 0.5% was used as a topical anesthetic. Proptosis was obtained by a retrobulbar injection of 1.0 cc of lidocaine hydrochloride and sterile water (1:1 solution). Eyes were prepared for surgery in a

sterile fashion. Pars plana vitrectomies were performed using an Ocutome system under an operating microscope (Zeiss Co., Model OPMI-6, Oberkochen, Germany) using a planoconcave vitrectomy lens. Following a superior fornix based peritomy, two 20-gauge sclerotomies were made at a distance of 2-3 mm posterior to the corneoscleral limbus at the 10 and 2 o'clock positions. A 4-mm infusion cannula, attached to a bottle of saline, was fixed in the temporal sclerotomy with a preplaced 6/0 vicryl suture. The posterior vitreous was removed as completely as possible prior to the injections. The PFCLs were transferred from the sterile containers to a 5-cc syringe through a 20-gauge needle and permeable membrane filters (Millipore, pore size=0.22  $\mu$ m). Fluid-fluid exchange was performed by injecting each studied PFCL intravitreally through the infusion cannula. Since PFCLs are heavier than saline, the former moved to the posterior pole, expelling the lighter saline through the nasal sclerotomy. Injection of the PFCL continued until it was seen to be exiting from the nasal sclerotomy site. The infusion cannula was then removed and the sclerotomy closed with a 6/0 vicryl suture. If the eye were hypotonus, a small amount of PFCL was injected through the pars plana via a 25-gauge needle. The entire exchange procedure required approximately 2 cc to 3 cc of the heavy liquid as replacement; with this method, we were able to replace 50% to 60% of vitreous with one of the three above mentioned liquids.

The PFCLs were removed from the eye exactly one hour after injection. To achieve this procedure, a 25-gauge needle, connected to an elevated (2 ft) bottle of infusion fluid, was introduced into the eye

via the temporal pars plana. The nasal sclerotomy was reopened and a suction probe was used to aspirate the PFCL. While the infusion was flowing, the suction probe was directed to the posterior pole and PFCL aspirated with 100 mmHg suction pressure. Following this procedure, the needle and the probe were withdrawn; the sclerotomy was closed with a 6/0 vicryl suture and the conjunctiva was stroked back to the limbus. Animals were then sacrificed with an intracardiac overdose of pentobarbital (100 mg/kg) under deep anesthesia, and eyes were enucleated for histopathologic studies.

For light and electron microscopy, eyes were fixed in half-strength Karnovsky's fixative. Specimens for light microscopy were embedded in Histo-resin (LKB) and 3  $\mu$  sections were cut and stained with toluidin blue. For electron microscopy, tissues were processed in Polybed and 70 Å sections were cut, post-stained with uranyl acetate and lead citrate and viewed with a Zeiss EM 10 electron microscope.

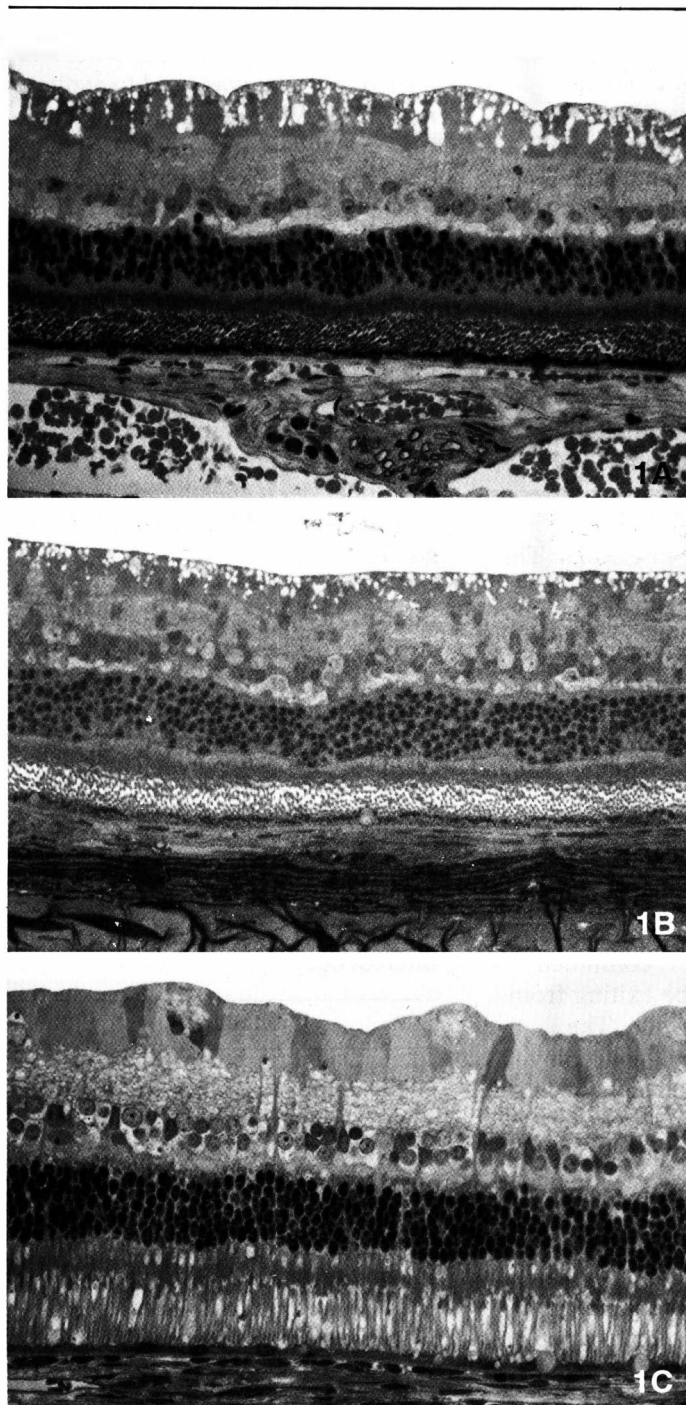
---

#### RESULTS

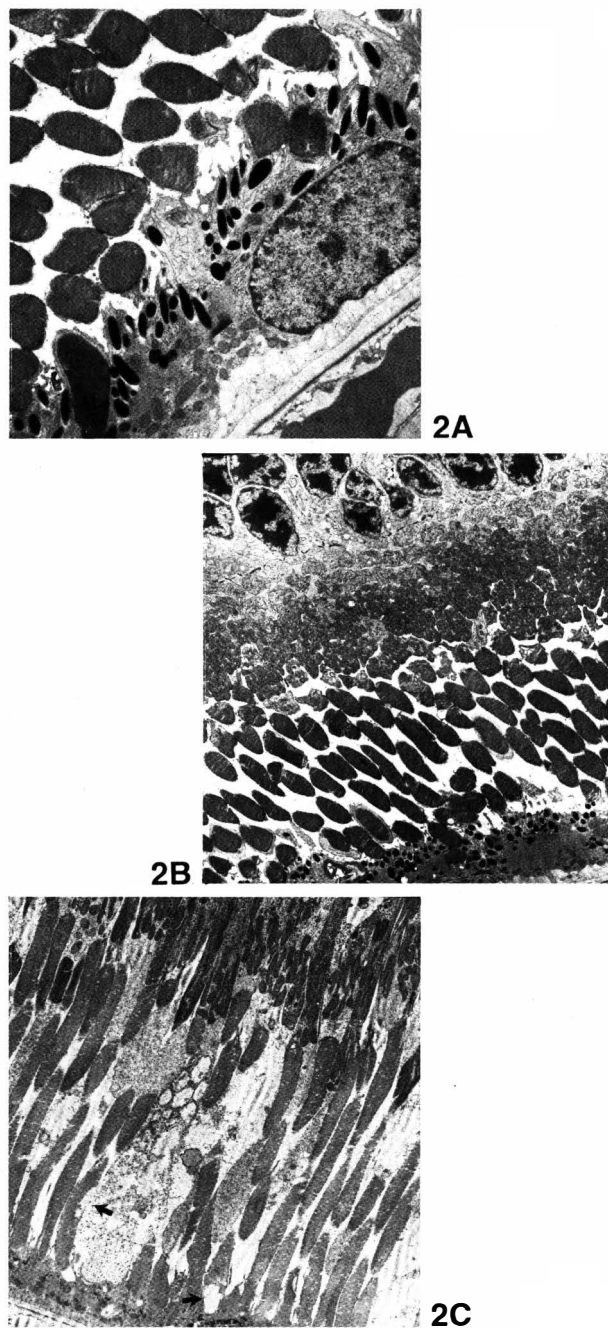
---

No complications were encountered during injection or after removal of the PFCLs. All of the eyes, both experimental and control, demonstrated a similar appearance on light microscopy (Fig. 1). The size, shape and number of nuclei in both the outer and inner nuclear layers were within normal limits. The thickness of the retina corresponded to that of normal retina, and the ganglion cell layer showed no abnormalities.

Transmission electron microscopy (Fig. 2) of the PFPE, PFTA, and saline-injected eyes revealed normal histology.



**Figure 1:** Light micrographs of enucleated eyes after fluid-fluid exchange. All of the eyes, whether injected with perfluoropolyether (A, x510), perfluorotributylamine (B, x320), or perfluorodecaline (C, x580), demonstrated a similar appearance by light microscopy.



**Figure 2:** Electron micrographs of enucleated eyes after fluid-fluid exchange. Note normal pigment epithelial-photoreceptor interface in the retinas of the PFPE (A, x9,768) and PFTA (B, x7,920) injected eyes. Irregularly shaped defects in the outer segment discs of the photoreceptors (arrows) of one PFDC-injected eye are apparent (C, x5,216).

However, two of the eight eyes in which PFDC had been injected showed irregularly shaped defects in the outer segment discs of the photoreceptors.

---

## DISCUSSION

---

The search for a new and better vitreous substitute has intensified recently because of problems related to the use of intraocular silicone oil that have recently been reported<sup>(23-25)</sup>. Perfluorocarbon derivatives are generally inert, and many of them are used as blood substitutes because they are good carriers of oxygen and carbon dioxide<sup>(26-29)</sup>.

PFPE, PFTA, and PFDC are fluorinated, synthetic, transparent compounds that provide excellent thermal and chemical stability. Their high specific gravity (1.88 to 1.94 g/mL) provide excellent mechanical tamponade, especially for inferior retinal breaks. The low surface tension (16-20 dynes/cm<sup>2</sup>) results in a high interface tension with saline, which limits their passage through retinal breaks. Their lower viscosity makes them very easy to handle, and they can be removed easily from the eye at any time during the surgical procedure. The higher viscosity (68 centistokes) of PFPE prevents formation of the fishegg phenomenon, which is so common with PFTA<sup>(14)</sup> and PFDC<sup>(15)</sup>.

The differences in physical characteristics between these three PFCLs were not clinically significant. Intraoperatively, the PFCL/saline interface was always visible, allowing easy fluid-fluid exchange. The refractive index is slightly dissimilar to saline, but this did not alter the refractive error of the eye, and conventional contact lenses could be used throughout surgery. PFDC had a slightly greater

tendency to disperse during injection and the interface was not as easily seen because its refractive index was more similar to that of saline. Removal of all of these PFCLs had to be done slowly and progressively, especially in the PFPE-injected eyes. We did not observe the formation of small bubbles (fish-egging phenomenon) when using these liquids in conjunction with the infusion fluid utilized in our experiments.

The complications resulting from the intraoperative use of PFCLs appear to be minimal. In some cases, as the liquid was injected, some dispersion did occur, with small droplets of PFCL being visible around the edge of the large bubble. Upon contact, however, these small droplets tended to coalesce with the large bubble. Furthermore, the low viscosity of the PFCLs used in this study permitted use of conventional 20-gauge microsurgical instruments.

In a previous study using PFTA, the outer segments of rabbit retina demonstrated irregularly shaped defects, referred to as "moth-eaten" by the authors, that reverted to normal after removal of the PFCL<sup>(14)</sup>. In another study, TERAUCHI and co-workers<sup>(16)</sup> observed toxic effects in eyes in which PFTA was used as a vitreous substitute for one month, but no structural changes were found if PFTA were removed from the eye one hour after injection. The irregularly shaped defects in the outer segment discs noted in our study were similar to those described by CHANG et al<sup>(14)</sup>. Since these changes are reported to be reversible, however, this effect may not preclude the use of PFDC intraoperatively.

We believe our results support the intraoperative use of these PFCLs. Our findings suggest that

one hour exposure of the retina to these PFCLs bubbles is not related to any significant toxic effect in the eyes of experimental rabbits. Additional studies are underway to further confirm the nontoxic nature of these PFCLs when used as short-term substitutes for vitreous.

---

## RESUMO

---

*Perfluorocarbonos líquidos (PFCLs) são compostos com uma gravidade específica maior que a água e utilizados como adjuntos no tratamento cirúrgico de casos complicados de descolamento de retina. Trinta e dois coelhos pigmentados foram submetidos a vitrectomia com injeção de PFCL dentro da cavidade vítrea: oito receberam perfluorotributilamino (PFTA); oito receberam perfluorodecalino (PFDC); oito receberam perfluoropoliéter (PFPE); os restantes oito olhos, que serviram de controle, receberam solução salina. Uma hora depois das injeções foi realizada troca PFCL/solução salina. Os animais foram então sacrificados, os olhos enucleados e processados para exames histológicos. À microscopia óptica nenhuma diferença significativa foi demonstrada entre os olhos com PFCLs comparando com os controles. A microscopia eletrônica revelou somente pequenas alterações, consistindo de alguns defeitos irregulares na forma dos segmentos externos dos fotorreceptores no grupo do PFDC. Estes fatos sugerem que o uso intra-operatório do PFTA, PFPE e PFDC, pelo menos em nosso modelo animal, não é associado com nenhuma patologia retiniana significativa.*

---

## ACKNOWLEDGEMENTS

The authors thank Christine Spee for her skilled technical assistance. The editorial assistance of Ann Dawson is greatly appreciated.

## REFERENCES

1. ARMALY MF: Ocular tolerance to silicones. I. Replacement of aqueous and vitreous by silicone fluids. *Arch Ophthalmol* 68:390-395, 1962.
2. LEE P, DONOVAN RH, MUKAI N, SCHEPENS CL, FREEMAN HM: Intravitreal injection of silicone: an experimental study. I. Clinical picture and histology of the eye. *Ann Ophthalmol* 1(2):15-25, 1969.
3. MUKAI N, LEE P, SCHEPENS CL: Intravitreal injection of silicone: an experimental study. II. Histochemistry and electron microscopy. *Ann Ophthalmol* 4:273-287, 1972.
4. LABELLE P, OKUN E: Ocular tolerance to liquid silicone: an experimental study. *Can J Ophthalmol* 7:199-204, 1972.
5. MUKAI N, LEE P, OGURI M, SCHEPENS CL: A long-term evaluation of silicone retinopathy in monkeys. *Can J Ophthalmol* 10:391-402, 1975.
6. OBER RR, BLANKS JC, OGDEN TE, PICKFORD M, MINCKLER DS, RYAN SJ: Experimental retinal tolerance to liquid silicone. *Retina* 3: 77-85, 1983.
7. CHAN C, OKUN E: The question of ocular tolerance to intravitreal liquid silicone: long-term analysis. *Ophthalmology* 93:651-660, 1986.
8. GONVERS M, HORNUNG JP, DE COURTEN C: The effect of liquid silicone on the rabbit retina: histologic and ultrastructural study. *Arch Ophthalmol* 104: 1057-1062, 1986.
9. PAREL JM: Silicone oils: physicochemical properties. In: *Retina*, Vol. 3, Glaser BM & Michels RG, editors; Ryan SJ, editor-in-chief. St. Louis, CV Mosby, pp. 261-277, 1989.
10. LEAN JS: Use of silicone oil as an additional technique in vitreoretinal surgery. In: *Retina*, Vol. 3, Glaser BM & Michaels RG, editors; Ryan SJ, editor-in-chief. St. Louis, CV Mosby, pp. 279-292, 1989.
11. HAIDT SJ, CLARK LC JR, GINSBERG J: Liquid perfluorocarbon replacement of the eye. *ARVO Abstracts. Invest Ophthalmol Vis Sci* 22(Suppl.): 233, 1982.
12. MIYAMOTO K, REFOJO MF, TOLENTINO FI, FOURNIER GA, ALBERT DM: Perfluoroether liquid as a long-term vitreous substitute: An experimental study. *Retina* 4:264-268, 1984.
13. MIYAMOTO K, REFOJO MF, TOLENTINO FI, FOURNIER GA, ALBERT DM: Fluorinated oils as experimental vitreous substitutes. *Arch Ophthalmol* 104:1053-1056, 1986.
14. CHANG S, ZIMMERMAN NJ, IWAMOTO T, ORTIZ R, FARIS D: Experimental vitreous replacement with perfluorotributylamine. *Am J Ophthalmol* 103:29-37, 1987.
15. HAMMER ME, RINDER DF, HICKS EL, YANG CH, HORNUNG CA: Tolerance of perfluorocarbons, fluorosilicone, and silicone liquids in the vitreous. In: *Proliferative vitreoretinopathy (PVR)*. Freeman HM & Tolentino FI, editors, New York, Springer-Verlag, pp. 156-161, 1988.
16. TERAUCHI H, OKINAMI S, KOZAKI Z, TANIHARA H, NAGATA M, SEGAWA Y: Experimental study on the effects of a replacement of the vitreous body with perfluorotributylamine on the rabbit eye. *Nippon Ganka Gankai Zasshi* 93:294-301, 1989.
17. NABIH M, PEYMAN GA, CLARK LC JR, HOFFMAN RE, MICELI M, ABOUSTEIT M, TAWAKOL M, LIU KR.: Experimental evaluation of perfluorophenathrene as a high specific gravity vitreous substitute: a preliminary report. *Ophthalmic Surg* 20:286-293, 1989.
18. FLORES-AGUILAR M, CRAPOTTA JA, MUNGUIA D, BERGERON-LYNN G, LONG D, WILEY CA, FREEMAN WR: Perfluorooctylbromide (PFOB) as a temporary vitreous substitute. *ARVO Abstracts. Invest Ophthalmol Vis Sci* 32(Suppl.):1225, 1991.
19. CHANG S: Low viscosity liquid fluorochemicals in vitreous surgery. *Am J Ophthalmol* 103:38-43, 1987.
20. CHANG S, REPUCCI V, ZIMMERMAN NJ, HEINEMANN MH, COLEMAN DJ: Perfluorocarbon liquids in the management of traumatic retinal detachments. *Ophthalmology* 96:785-792, 1989.
21. CHANG S, LINCOFF H, ZIMMERMAN NJ, FUCHS W: Giant retinal tears: Surgical techniques and results using perfluorocarbon liquids. *Arch Ophthalmol* 107:761-766, 1989.
22. CHANG S, OZMERT E, ZIMMERMAN NJ: Intraoperative perfluorocarbon liquids in the management of proliferative vitreoretinopathy. *Am J Ophthalmol* 106:668-674, 1988.
23. MC CUE BW II, DE JUAN E JR, LANDERS MB III, MACHEMER R: Silicone oil in vitreoretinal surgery part 2: Results and complications. *Retina* 5:198-205, 1985.
24. CASSWELL AG, GREGOR ZJ: Silicone oil removal. I. The effect on the complications of silicone oil. *Br J Ophthalmol* 71:893-897, 1987.
25. LEWIS H, BURKE JM, ABRAMS GW, AABERG TM: Persilicone proliferation after vitrectomy for proliferative vitreoretinopathy. *Ophthalmology* 95:583-591, 1988.
26. BIRO GP, BLAIS P: Perfluorocarbon blood substitutes. *Crit Rev. Oncol Hematol* 6:311-374, 1986.
27. GEYGER RP: Whole animal perfusion with fluorocarbon dispersions. *Fed Proc* 29:1758-1763, 1970.
28. RIESS JG, LE BLANC M: Perfluoro compounds as blood substitutes. *Angewandte Chemie* 17:621-634, 1978.